The New England
Journal of Medicine

Copyright, 1955, by the Massachusetts Medical Society

Volume 252 MAY 12, 1955 Number 19

# PROPHYLAXIS AGAINST GROUP A STREPTOCOCCI IN RHEUMATIC FEVER*

## The Use of Single Monthly Injections of Benzathine Penicillin G

GENE H. STOLLERMAN, M.D.,† JEROME H. RUSOFF, M.D.,‡ AND ILSE HIRSCHFELD, M.D.§

NEW YORK CITY

THE prevention of recurrences of rheumatic fever depend on the protection of the patient against infection with Group A streptococci. The daily oral administration of sulfonamides or penicillin has been employed with considerable success for this purpose.[1] The major limitation of continuous oral chemoprophylaxis is that patients are apt to forget to take their medication regularly. For this reason the administration of penicillin parenterally by infrequent injections may afford a more reliable method of prophylaxis.

Preliminary studies indicate that the administration of single monthly injections of benzathine penicillin to rheumatic subjects confers a high degree of protection against infection with Group A streptococci.[2-4] A single intramuscular injection of this long-acting repository penicillin compound is also highly effective in the prompt cure of streptococcal pharyngitis, the permanent eradication of streptococci from the throat and apparently in the prevention of initial attacks of rheumatic fever.[5-9]

This report of a two-year study presents further confirmatory evidence that monthly injections of benzathine penicillin offer a highly effective, safe and practical method of prophylaxis against rheumatic recurrences.

### METHODS

Patients receiving injections of benzathine penicillin G¶ ranged in age from six to sixteen years and had suffered an attack of acute rheumatic fever within eighteen months at the time prophylaxis was initiated. All attended the Irvington House outpatient clinic and lived in congested areas of New York City where the prevalence of rheumatic fever is known to be relatively high. At each clinic visit (every four weeks) they were examined, throat cultures were made, blood was obtained by venipuncture for determination of antistreptolysin O titer and erythrocyte sedimentation rate, and at six-month intervals electrocardiograms were obtained and fluoroscopy was performed by one of the physicians engaged in the study. Patients who failed to keep a clinic appointment were seen within forty-eight hours by a visiting nurse, who administered benzathine penicillin and obtained throat swabs for culture and blood specimens for streptococcal-antibody determinations. In addition, the nurse visited the patients at home to investigate reported illness and made throat cultures when respiratory infection was encountered. One of the physicians engaged in the study made a home visit when symptoms suggestive of rheumatic fever or a related complication were reported. In several cases the patients were hospitalized at Irvington House for further observation. Benzathine penicillin G was injected in a dose of 1,200,000 units contained in a volume of 2 cc. This dose was supplied in a disposable cartridge and was injected deeply into the upper outer quadrant of the buttock.

Between September, 1952, and August, 1954, 145 patients received this treatment for a total of 2193 patient months, an average of approximately 20 months per patient (Table 1). In addition to the outpatients treated, 265 patients hospitalized at Irvington House in the acute and convalescent stages of rheumatic fever received single monthly injections of 1,200,000 units of benzathine penicillin. Because they lived in an isolated environment with minimum exposure to Group A streptococci, they are analyzed as a separate group and are combined with outpatients only for purposes of determining the over-all frequency of toxic reactions and other complications of this form of prophylaxis.

The average attendance at each clinic was 87 per cent of scheduled appointments. Since every child who failed to keep a clinic appointment received an

*From Irvington House and the Department of Medicine, New York University College of Medicine.

Supported in part by grants from the Masonic Foundation for Medical Research and Human Welfare, Westchester Heart Association and Wyeth Laboratories.

†Instructor in medicine, New York University College of Medicine; medical director, Irvington House; assistant attending physician, New York University Medical Division, Bellevue Hospital.

‡Research associate, Irvington House; associate medical director, Irvington House, Prophylaxis Clinic.

§Research associate, Irvington House; associate medical director, Irvington House, Prophylaxis Clinic.

¶Kindly supplied as Bicillin by Wyeth Laboratories, Philadelphia.

injection of benzathine penicillin by the nurse who made a home visit within two days, there was no interruption of the prophylactic regimen. Twelve patients left the project either because of poor co-operation or as a result of moving to a distant area.

To compare the frequency of rheumatic recurrences in this group with that of patients receiving other forms of prophylaxis, rheumatic subjects of similar age, geographic distribution and stage of illness, who attended the Bellevue Hospital Children's Cardiac Clinic,* were followed. One hundred and eleven patients in this group received 200,000 units of penicillin by mouth, and 73 received 1.0 gm. of sulfadiazine by mouth, as a single dose.

TABLE 1. *Patients Treated with 1,200,000 Units of Benzathine Penicillin Administered Intramuscularly Every Four Weeks.*

| GROUP | NO. OF PATIENTS | PATIENT MONTHS | AVERAGE FOLLOW-UP PERIOD | AVERAGE CLINIC ATTENDANCE | FOLLOW-UP COVERAGE BY VISITING NURSE | NO. OF PATIENTS DROPPED |
|---|---|---|---|---|---|---|
| | | | mo. | % | % | |
| Outpatients | 145 | 2893 | 20.0 | 87 | 100 | 12 |
| Inpatients | 265 | 1960 | 7.4 | — | — | — |

Throat cultures were made by direct inoculation of throat swabs on 5 per cent sheep-blood agar. Attempts were made to group and type all strains of beta-hemolytic streptococci by standard methods.[10] Penicillin sensitivity of organisms was determined by a tube-dilution method employing a strain of *Staphylococcus aureus* H as a standard reference.[11] Antistreptolysin O determinations were performed by a modification of Todd's[12] method. All apparent increases of antistreptolysin O titers were confirmed by simultaneous reassay of the stored samples of serums obtained by serial bleedings. A significant rise in titer was regarded as an increase of 2 tubes in the dilution method, representing an increase of 0.2 in the logarithm of the serum-dilution factor. In a few cases in which patients with positive throat cultures failed to show a rise in antistreptolysin O titer, determinations of antihyaluronidase[13] and antistreptokinase[14] were performed.

## RESULTS

### Recurrences of Rheumatic Fever

No recurrences of rheumatic fever were observed in the 145 patients who received monthly injections of benzathine penicillin (Table 2). The group receiving benzathine penicillin intramuscularly appeared to compare favorably with those receiving oral prophylaxis although the limited size of the groups and duration of the study did not warrant a statistical test of significance. There were 2 rheumatic recurrences among 111 patients who received 200,000 units of penicillin by mouth daily (170 patient years). Five of 73 patients receiving 1.0 gm. of sulfadiazine daily suffered rheumatic recurrences (130 patient years). All patients who suffered recurrences while receiving daily oral prophylactic medication admitted that there were frequent breaks in the regimen because of forgetfulness.

### Throat Cultures

Of 2716 throat cultures made from patients receiving benzathine penicillin only 3 were positive for Group A streptococci (2 were obtained from the same patient on different occasions and were due to different serologic types of Group A streptococci). Only 1 patient had a clinically apparent pharyngitis associated with a positive culture.

To obtain some indication of the prevalence of infection with Group A streptococci in the community throat cultures were taken during the spring of 1953 and 1954 from a similar patient population not receiving any form of chemoprophylaxis. These patients attended either the allergy, tuberculosis follow-up or children's cardiac clinic of Bellevue Hospital. During the same period cultures were also made from the throats of rheumatic subjects receiving either penicillin or sulfadiazine by mouth as prophylaxis against rheumatic recurrences.

Of 269 patients in the untreated control group 52 (19.3 per cent) were found to be harboring Group A streptococci during two spring seasons. In this group, with few exceptions, only 1 throat culture per patient was made. Of 75 patients receiving sulfadiazine 8 (10.7 per cent) were positive for Group A streptococci; an average of 1.8 cultures per patient was made during two spring seasons. Of 99 patients receiving 200,000 units of penicillin by mouth daily 13 (13.1 per cent) were positive for Group A streptococci; an average of 1.6 cultures per patient was made in this group. Of the 145 patients receiving benzathine penicillin intramuscularly during the two spring seasons there was one positive culture for Group A streptococci. Each patient's throat was cultured 6 times during this period. There were only 3 positive cultures of 2716 made in this group during the entire period of the study (Table 3).

TABLE 2. *Recurrences of Rheumatic Fever in Patients Receiving Prophylaxis against Infections with Group A Streptococci.*

| DRUG | AMOUNT | FREQUENCY OF ADMINISTRATION | NO. OF PATIENTS | PATIENT YEARS | NO. OF RECURRENCES |
|---|---|---|---|---|---|
| Benzathine penicillin | 1,200,000 units | Every 4 wk. | 145 | 242 | 0 |
| Penicillin (by mouth) | 200,000 units | Daily | 111 | 170 | 2 |
| Sulfadiazine | 1.0 gm. | Daily | 73 | 130 | 5 |

*We are indebted to Drs. Ann Kuttner and Janet Baldwin for permission to report these observations made on their patients.

### Antistreptolysin O Titer

The antistreptolysin O serum titer was determined every four weeks in patients receiving benzathine penicillin intramuscularly. A significant rise in titer was noted in but 3 patients. The antistreptolysin O titers in the remainder of the group either fell gradually or remained constant. The range and distribution of titers at various intervals during the study are shown in Table 4. Most patients admitted to this study were convalescent approximately a year from the preceding attack and had received continuous prophylaxis from the onset of the attack. The initial antistreptolysin O titers are therefore relatively low when compared with those of patients observed during the early stage of acute rheumatic fever. By the end of a year the rate of patients with titers remaining above 200 units was 9.7 per cent. By the end of two years only 2.9 per cent of patients still had an antistreptolysin O titer greater than 200 units (Table 4).

Of the total number of patients receiving injections of benzathine penicillin monthly, only 4 gave evidence of recurrence of infection with Group A streptococci during the period of study. One patient had a clinically apparent pharyngitis associated with a positive culture and a rise in antistreptolysin O titer. Two patients had a rise in antistreptolysin O titer as sole evidence of streptococcal infection. One patient had a positive culture without an associated rise in antistreptolysin O titer and without clinical signs or symptoms of pharyngitis. In the remainder of this group all respiratory infections were found to be unassociated with either positive cultures for Group A streptococci or a rise in titer.

TABLE 3. *Throat Cultures Obtained from Patients Receiving Prophylaxis against Infections with Group A Streptococci.*

| GROUP | NO. OF PATIENTS | NO. OF CULTURES | POSITIVE CULTURES | PATIENTS WITH POSITIVE CULTURES |
|---|---|---|---|---|
| Patients receiving benzathine penicillin* | 145 | 2716(18.7)‡ | 3 | 2(1.4%) |
| Patients receiving penicillin by mouth† | 99 | 155(1.6)‡ | 14 | 13(13.1%) |
| Patients receiving sulfadiazine† | 75 | 133(1.8)‡ | 9 | 8(10.7%) |
| Controls | 269 | 280(1.0)‡ | 53 | 52(19.3%) |

*Cultures made every 4 wk. throughout study.
†Cultures made only during March to June, 1953, & 1954.
‡Figures in parentheses represent number of cultures per patient.

### Changes in Cardiac Lesions During Prophylaxis

Of the patients receiving benzathine penicillin there were 71 who had no clinical evidence of heart disease at the time of admission to the study (Table 5). No signs of organic heart disease developed in these cases during the two-year period of observation. Of 74 patients who had clinically apparent rheumatic heart disease on admission to the study 8 were reclassified as having "no heart disease" at the end of the study when organic murmurs had disappeared and heart size had reverted to normal. Five additional patients showed improvement in cardiac status on the basis of the disappearance of an organic murmur or return of heart size to normal.

Evidence of progression of heart disease appeared in only 3 patients, a new organic murmur appearing in 2 and progressive cardiac enlargement in the other, who also had marked aortic insufficiency. The 2 patients with the new organic heart murmurs in the absence of evidence of either active rheumatic fever or streptococcal infection deserve special comment. In 1, an aortic diastolic murmur had been present from the acute stage of the disease. This remained unchanged while he received prophylaxis, but a mitral diastolic murmur that became progressively louder was heard at the apex three months after admission to the study and seventeen months after the acute attack. This was followed by the gradual appearance of a presystolic murmur in the same region. These new murmurs gradually became softer five months after their appearance and at this writing have almost disappeared. The second patient had had mitral systolic and diastolic murmurs from the acute stage of the disease. These murmurs did not change during

TABLE 4. *Antistreptolysin O Titers in the Blood of Outpatients* with Rheumatic Fever Receiving 1,200,000 Units of Benzathine Penicillin Monthly.*

| RANGE OF TITER | FREQUENCY OF TITERS IN RANGE | | | | |
|---|---|---|---|---|---|
| | AT 0 MO.† | AT 6 MO.‡ | AT 12 MO.§ | AT 18 MO.¶ | AT 24 MO.‖ |
| units/cc. | % | % | % | % | % |
| 0-200 | 83.7 | 88.4 | 90.3 | 92.4 | 97.1 |
| 250-333 | 15.0 | 11.6 | 9.7 | 7.6 | 2.9 |
| 400 or over | 1.3 | 0 | 0 | 0 | 0 |

*All patients convalescent approximately 1 yr. from onset of preceding attack of rheumatic fever. Initial titers therefore relatively low, compared with those of patients in early stages of acute rheumatic fever.
†153 patients.
‡147 patients.
§124 patients.
¶118 patients.
‖104 patients.

TABLE 5. *Changes in Cardiac Status.**

| GROUP | NO. AT ADMISSION TO STUDY | CASE RECLASSIFIED AS "NO HEART DISEASE" | PROGRESSION OF RHEUMATIC HEART DISEASE† | IMPROVEMENT IN CARDIAC STATUS‡ |
|---|---|---|---|---|
| Patients with rheumatic heart disease | 74 | 8 | 3 | 5 |
| Patients with no heart disease | 71 | — | 0 | — |

*Patients admitted to study approximately 1 yr. from onset of last attack of rheumatic fever; no evidence of rheumatic activity during study.
†Appearance of new organic murmur or progressive cardiac enlargement.
‡Disappearance of organic murmur or return of heart size to normal.

the period of observation, but a soft, early diastolic aortic murmur was heard consistently five months after admission to the study and nineteen months after the acute attack had apparently subsided. This murmur had been heard transiently by one of us (G.H.S.) twelve months before its reappearance during the study.

With these exceptions all patients showed either improvement or no significant change in cardiac status during the two-year period of observation.

### Reactions in Patients Receiving Benzathine Penicillin Intramuscularly

A total of 4871 injections of benzathine penicillin were administered to 410 patients. The average number of injections per patient was approximately twelve. Most patients experienced deep muscle soreness and tenderness that lasted for one to three days.

TABLE 6. *Reactions in 410 Patients Receiving 4871 Injections of Benzathine Penicillin* Intramuscularly.*

| MANIFESTATION | NO. OF PATIENTS | RECURRENCES‖ |
|---|---|---|
| Urticaria or angioneurosis† | 4(1.0%) | 0 |
| "Serum sickness"‡ | 1(0.2%) | — |
| Generalized rash (nonurticarial)† | 8(2.0%) | 1 |

*Average of 12 per patient.
†Mild, transient, persisting for 2-4 days.
‡Arthritis, angioneurotic edema & urticaria, subsiding in 5 days.
‖Reappearing on subsequent injections of benzathine penicillin.

This reaction, although somewhat unpleasant, was usually accepted without undue complaint. Only 1 patient dropped out of the study solely for this reason. No abscess developed at the injection site. Occasionally, when injections were made too superficially (particularly into obese buttocks), leakage of the compound into subcutaneous fat resulted in the formation of tender nodules, which persisted at times for several weeks. In general, local reactions, though sometimes annoying, did not constitute a serious problem.

Transient low-grade fever was sometimes associated with local pain and tenderness (in about 10 per cent of patients). These febrile reactions disappeared within twenty-four to forty-eight hours as the local reaction subsided.

Reactions assumed to be due to penicillin hypersensitivity occurred in 5 patients (Table 6). Three had mild generalized urticaria, 1 had urticaria associated with angioneurotic edema of the face and hands, and 1 had a "serum-sickness" type of reaction consisting of fever, angioneurotic edema and polyarthralgia. In all but the last patient the urticarial reactions were transient, subsiding in two to four days although detectable levels of penicillin persisted in the blood for several weeks. It was decided, therefore, to resume injections of benzathine penicillin on schedule. This was done without the reappearance of any further allergic manifestations. The "serum-sickness" syndrome that appeared in 1 patient subsided within a week. Because of the more severe type of reaction no attempt was made to resume penicillin prophylaxis in this patient.

Nonspecific, nonurticarial rashes appeared in 8 patients during the period of study. The relation of these rashes to penicillin therapy was difficult to determine. All were transient. Treatment was not permanently interrupted, and the rashes did not reappear when injections were resumed except in 1 patient who had a recurrent, dry pruritic rash on several occasions that appeared without definite relation to penicillin injections.

### Other Infections

Upper respiratory infections (excluding afebrile coryza) that were nonstreptococcal occurred 252 times in 104 patients. Nine patients had at least 4 upper respiratory infections. In 2 cases these were due to recurrent bouts of nonstreptococcal tonsillitis. Three patients had tonsillitis that was apparently due to coagulase-positive, hemolytic *Staph. aureus* and was cured by daily doses of 600,000 units of aqueous procaine penicillin or 2 gm. of chlortetracycline daily by mouth for seven days. Nine patients had seventeen varying manifestations of infections possibly due to staphylococci but not proved by culture (furuncles, styes or abscesses). There were, in addition, 4 cases of acute otitis media of presumably nonbacterial origin, 1 of atypical pneumonia, and 2 of bacterial endocarditis due to *Streptococcus viridans*. One of the last was an outpatient whose disease followed extraction of a tooth; additional prophylactic doses of aqueous procaine penicillin had not been administered before tooth extraction, despite routine instructions to all patients to do so. In the second patient subacute bacterial endocarditis developed without apparent inciting cause while monthly injections of benzathine penicillin were being given during hospitalization at Irvington House.

In both cases *Str. viridans* was isolated from blood cultures. Both patients were cured by a six-week course of crystalline penicillin G given in large doses (up to 10,000,000 units daily) for the first two weeks and lower doses (2,500,000 units daily) subsequently. The strains of *Str. viridans* isolated were sensitive to 0.1 and 0.3 units of penicillin per cubic centimeter of culture medium, respectively.

Finally, it should be noted that 27 patients received additional short-term antibiotic treatment with various drugs for different infections on 35 occasions. Six times such treatment was administered by us, and in the remaining cases by family doctors or at other clinics.

## DISCUSSION

A carefully controlled study of the effectiveness of various methods of prophylaxis was beyond the scope of this project. Such a study would require random allocation of large numbers of patients to each treat-

ment group within the same clinic. The method of examination and the diagnostic tests performed would also have to be uniform in all treatment groups. Because such large numbers of patients could not be managed the purpose of this study was to obtain some impression of the degree of protection against streptococcal infection that benzathine penicillin injections conferred on a highly susceptible group of rheumatic subjects exposed to challenging environmental conditions.

In the absence of an available untreated control group it was considered of some value to compare the frequency of rheumatic recurrences in the group treated with benzathine penicillin with that of the groups treated with sulfonamides and penicillin by mouth, particularly since the latter two groups were of comparable age, resided in the same geographic area and were in the same stage of the disease. This was done to ascertain whether rheumatic recurrences were taking place with expected frequency in the groups receiving prophylaxis by compounds administered orally.

The annual recurrence rate in New York City during the first two years after an attack of rheumatic fever was about 15 per cent in the years between 1936 and 1942 when antistreptococcal prophylaxis was not generally employed.[1] The annual rate of recurrence in patients in this study who received either sulfadiazine or penicillin by mouth was 2.3 per cent, representing a decrease of 85 per cent that may have been related to factors other than the employment of oral antibiotic prophylaxis. It is of interest, however, that the combined results of many *controlled* studies during the past fifteen years also indicate a reduction of about 85 per cent in the frequency of rheumatic recurrences in sulfonamide-treated groups compared with untreated, control groups.[15]

There is reason to believe, therefore, that rheumatic recurrences were encountered with expected frequency in patients receiving oral prophylaxis during the course of this study. The total absence of recurrences in the group treated with benzathine penicillin may therefore be significant. An adequate comparison of the various forms of prophylaxis employed, however, will require more extensive observations on larger numbers of patients in more carefully controlled experiments. Such studies are now in progress.

More impressive, perhaps, than the absence of recurrences are the data indicating a very low prevalence of infection with Group A streptococci in patients who received injections of benzathine penicillin. That this was not the result of lack of exposure to Group A streptococci is indicated by the relatively large number of throat cultures positive for Group A streptococci in the untreated control group and in patients who received oral forms of prophylaxis.

These results are in agreement with our preliminary observations[2,3] and with the reports of others that single injections of benzathine penicillin are effective in protecting patients with rheumatic fever against Group A streptococci[4] and in preventing new streptococcal infections among young adults exposed to epidemic conditions.[6-8]

Extended observations are necessary to determine whether careful prophylaxis continued over many years will abort the delayed appearance of rheumatic heart disease in rheumatic subjects that was described by Bland and Jones[16] during a twenty-year study. Although the period of observation reported here is relatively brief, it is of some interest that in this study patients who recovered from an attack of rheumatic fever without apparent cardiac lesions did not give evidence of cardiac disease during the subsequent period of prophylaxis. Because 2 patients with rheumatic heart disease manifested new organic heart murmurs during the study, it appears that rheumatic heart disease occasionally progresses at subclinical levels of rheumatic activity in the absence of additional streptococcal insult. Such a progression appears to be relatively infrequent, however, when rheumatic recurrences are averted, unless the disease is advanced and severe.

The major reservation to the acceptance of the prolonged intramuscular administration of benzathine penicillin, other than the inconvenience of somewhat painful monthly injections, appears to be the question of the development of penicillin hypersensitivity. The results observed to date do not indicate that this regimen has been attended by any greater degree of penicillin hypersensitivity than might be expected with the use of any other penicillin compound administered parenterally in similar doses. Indeed, the penicillin reactions noted have been, with 1 exception, mild and transient and have not required interruption of the regimen. It might be noted that so-called penicillin hypersensitivity is a form of drug allergy and does not necessarily follow the classic patterns of hypersensitivity observed with the administration of whole antigens. Our experience to date with the parenteral use of benzathine penicillin (including this study) consists of the administration of 6624 intramuscular injections administered to 553 rheumatic subjects for periods ranging from ten to twenty-four months (an average of 12 injections per patient). The rate of penicillin reactions has been 1.3 per cent, and all but one reaction has been mild and transient and has not reappeared on resumption of administration of the same compound. It is not generally recommended, however, that patients who have had reactions to penicillin receive injections of benzathine penicillin. In such patients treatment with sulfadiazine or other antibiotics is recommended.

## Summary and Conclusions

No recurrences of rheumatic fever were observed among 145 patients with rheumatic fever who received monthly injections of 1,200,000 units of benzathine penicillin during a two-year period.

Evidence of infection was noted in but 4 of these patients during the period of study. Only 1 of the 4 had a clinically apparent pharyngitis associated with a positive culture for Group A streptococci and a rise in antistreptolysin O titer. The remainder had either a rise in antibody or a positive culture for Group A streptococci as sole evidence of infection.

Cardiac lesions progressed in 3 patients who had rheumatic heart disease at the beginning of the study. Those who did not have apparent rheumatic heart disease at the beginning of the study did not have cardiac lesions subsequently.

Reactions considered to be due to penicillin hypersensitivity occurred in 5 of 410 patients who received an average of 12 monthly injections per patient.

Single monthly injections of 1,200,000 units of benzathine penicillin confer a high degree of continuous protection against infection with Group A streptococci and afford a reliable means of protecting the patient against recurrences of rheumatic fever.

We are indebted to Miss Lucille Blumenkranz, visiting nurse and clinic supervisor, Miss Marie Payne, clinic secretary, and Misses Dorothy Grinnell and Catherine Cedrone, laboratory technicians, for their assistance.

## References

1. Stollerman, G. H. Use of antibiotics for prevention of rheumatic fever. *Am. J. Med.* **17**:757-767, 1954.
2. Stollerman, G. H., and Rusoff, J. H. Prophylaxis against group A streptococcal infections in rheumatic fever patients: use of new repository penicillin preparation. *J.A.M.A.* **150**:1571-1575, 1952.
3. Stollerman, G. H., Rusoff, J. H., and Hirschfeld, I. Prophylaxis against group A streptococci in rheumatic fever patients by use of single monthly injections of N, N'Dibenzylethylenediamine Dipenicillin G (Bicillin): progress report. In *Antibiotics Annual 1953-1954*. Edited by H. Welch and F. Marti-Ibáñez. 632 pp. New York: Medical Encyclopedia, Incorporated, 1953. P. 114.
4. Diehl, A. M., Hamilton, T. R., Keeling, I. C., and May, J. S. Long-acting repository penicillin in prophylaxis of recurrent rheumatic fever. *J.A.M.A.* **155**:1466-1470, 1954.
5. Breese, B. B. Treatment of beta hemolytic streptococcic infections in home. *J.A.M.A.* **152**:10-16, 1953.
6. Chamovitz, R., Catanzaro, F. J., Stetson, C. A., and Rammelkamp, C. H., Jr. Prevention of rheumatic fever by treatment of previous streptococcal infections. I. Evaluation of benzathine penicillin G. *New Eng. J. Med.* **251**:466-471, 1954.
7. Wannamaker, L. W., et al. Effect of penicillin prophylaxis on streptococcal disease rates and carrier state. *New Eng. J. Med.* **249**: 1-7, 1953.
8. Feldman, H. A., Bernstein, S. H., and Williams, H. B. Treatment of acute micrococcic (streptococcic) pharyngitis with penicillin. *J.A.M.A.* **155**:109-111, 1954.
9. Breese, B. B. Successful treatment of beta hemolytic streptococci infection in children with single injection of repository penicillin (Bicillin). *J. Pediat.* (in press).
10. Swift, H. F., Wilson, A. T., and Lancefield, R. C. Typing group A hemolytic streptococci by M precipitation reaction in capillary pipettes. *J. Exper. Med.* **78**:127-133, 1943.
11. *Methods in Medical Research*. Edited by V. R. Potter. Vol. 1. *Assay of Antibiotics*. Edited by H. Welch. 372 pp. Chicago: Year Book Publishers, 1948.
12. Todd, E. W. Antigenic streptococcal hemolysin. *J. Exper. Med.* **55**:267, 1932.
13. Harris, S., and Harris, T. N. Measurement of neutralizing antibodies to streptococcal hyaluronidase by turbiometric method. *J. Immunol.* **63**:233-247, 1949.
14. Christensen, L. R. Methods for measuring activity of components of streptococcal fibrinolytic system, and streptococcal desoxyribonuclease. *J. Clin. Investigation* **28**:163-172, 1949.
15. Rammelkamp, C. H., Jr., et al. Prevention of rheumatic fever. In *Rheumatic Fever: A symposium held at the University of Minnesota on November 29, 30, and December 1, under the sponsorship of the Minnesota Heart Association*. Edited by L. Thomas. 349 pp. Minneapolis: University of Minnesota Press, 1952.
16. Bland, E. F., and Jones, T. D. Rheumatic fever and rheumatic heart disease: twenty year report on 1000 patients followed since childhood. *Circulation* **4**:836-843, 1951.

# MANAGEMENT OF POSTOPERATIVE PSEUDOMEMBRANOUS ENTEROCOLITIS WITH SHOCK*

## Report of a Case with Recovery

Ole T. Jonassen, M.D.,† Sidney M. Fierst, M.D.,‡ and John J. Cincotti, M.D.§

BROOKLYN, NEW YORK

ALTHOUGH postoperative enterocolitis was first reported by Finney[1] in 1893 and Dearing and Heilman[2] mention cases encountered before the use of antibiotics, the syndrome known variously as pseudomembranous enteritis, staphylococcal enterocolitis and acute necrotizing enteritis has rarely been described until recently. The apparent increase seems to coincide with the greater use of the broad-spectrum antibiotics, particularly of the tetracycline derivatives. The depression of the normal bacterial flora upsets the natural symbiotic balance, and may produce a fertile field for the unrestricted development of certain resistant virulent bacterial strains. Coagulase-positive hemolytic staphylococci have been incriminated in the fulminating enterocolitis.

Two patients with staphylococcic enterocolitis were recently encountered on the Surgical Service of the Brooklyn Veterans Administration Hospital. The first case was fulminating, and the patient died shortly after the onset of shock, nine days after gastrectomy. Three weeks later, on the same ward, a second patient with this syndrome was encountered. This case is reported in detail because of the interesting epidemiologic probabilities and since it represents recovery from pseudomembranous staphylococcal enterocolitis after the onset of shock.

*From the Surgical and Medical services, Veterans Administration Hospital, and the Department of Medicine and Surgery, State University of New York College of Medicine.

†Senior resident in surgery, Veterans Administration Hospital.

‡Clinical assistant professor of medicine, State University of New York College of Medicine; attending physician, Veterans Administration Hospital; physician-in-charge, Gastrointestinal Clinic, Kings County and Maimonides hospitals.

§Clinical associate professor of surgery, State University of New York College of Medicine; chief of surgery, Veterans Administration Hospital.

## Case Report

A 50-year-old man was admitted to the Gastroenterology Section of the Brooklyn Veterans Administration Hospital on March 29, 1954, for the management of pyloric obstruction due to a duodenal ulcer. His illness began in 1944 with epigastric pain and vomiting. After an episode of hematemesis and epigastric pain in 1945 a perforated duodenal

ulcer was repaired. In 1952 nausea and vomiting recurred. At this time he also had diarrhea with the passage of 10 to 12 loose, watery stools lasting for 2-week periods and recurring every 2 or 3 months. *Shigella alkalescens* was isolated from the stools on only one occasion in spite of repeated stool examinations. Two weeks before admission nausea and vomiting after meals became very severe.

Physical examination revealed a well nourished, well developed man. The only objective finding was an incisional scar in the right pararectus area. The hemogram, urinalysis and stool examinations were noncontributory. Protein and electrolyte values were normal. A gastrointestinal x-ray series disclosed a deformed duodenal cap and 60 per cent gastric residue after 4 hours. Barium-enema examination showed a normal colon.

The blood pressure was 150/90; the pulse was 80, and the respirations 20.

The morning and evening gastric aspirations 4 hours after meals persistently yielded 250 to 750 cc. Medical therapy was therefore abandoned in favor of surgery. On April 20, under cyclopropane endotracheal anesthesia, an 80 per cent gastric resection was performed. A scarred, penetrating duodenal ulcer was removed, and a postcolic isoperistaltic Hoffmeister anastomosis was created. A Penrose drain was placed in Morrison's pouch and brought out through a stab wound.

On the 2d postoperative day a severe pharyngitis, with a temperature of 101.3°F., developed. The penicillin and streptomycin that he had received postoperatively were discontinued in favor of 250 mg. of oxytetracycline 4 times daily. Active bowel sounds were heard, and the Levin tube was removed. On the following day the temperature was 99.7°F., and the pharyngitis seemed improved. Late that evening, after 30 hours of oxytetracycline therapy, the passage of watery stools was noted. By the morning of the 4th postoperative day 20 watery stools, of 200 to 300 cc. each, had been passed. During this period increasing nausea and vomiting occurred, and abdominal tenderness and distention appeared. The gastric tube was replaced, but only a small quantity of fluid was obtained. One liter of 5 per cent glucose and saline solution and 1 liter of 5 per cent glucose and water were administered that night. At 6 a.m. on the 4th day the blood pressure had dropped to 104/70, and the temperature had risen to 104.5°F.; the pulse was weak and thready at a rate of 140 per minute. The hemoglobin and hematocrit remained stable. There was no evidence of intra-abdominal bleeding or peritonitis. At 8 a.m. the blood pressure was unobtainable. Polyethylene catheters were inserted into the superior vena cava and into the left saphenous vein. Oxytetracycline was discontinued, and 400 mg. of erythromycin was given intravenously; 130 drops of norepinephrine per minute, in a concentration of 32 mg. per 1000 cc. of distilled water, was required to maintain a systolic blood pressure of 90. An electrocardiogram revealed a sinus tachycardia.

Approximately 12 hours after the onset of the diarrhea, the 1st pseudomembrane was passed as a perfect cast of intestinal epithelium with a viscid lemon-lime-colored liquid stool. Smears of the stool showed gram-positive cocci in clumps and scattered gram-negative bacilli. Cultures revealed a predominance of staphylococci (Fig. 1).

During the 4th postoperative day the patient became increasingly lethargic. Palpation of the abdomen demonstrated moderate tenderness and distention. There was dullness to percussion, with evidence of ascites. Bile-stained serous fluid that coagulated on standing flowed from the Penrose drain. Therapy consisted of maintenance of blood pressure with nor-epinephrine and the administration of 11 liters of fluid, electrolytes and whole blood to offset a calculated loss of 10 liters (Fig. 2). Twelve hours after the onset of shock, 25 mg. of ACTH was administered intravenously over an 8-hour period, and 300 mg. of cortisone was given intramuscularly.

On the morning of the 5th day, 24 hours after the onset of shock, although the pressure in the brachial artery could not be obtained owing to marked arterial constriction and edema about the antecubital fossa, the femoral blood pressure fluctuated from 100 to 170. The patient continued to pass 6 to 10 loose stools containing pseudomembranous casts of the bowel. Fluid and electrolyte solution were administered to meet the losses from urine, gastric suction, abdominal drainage and diarrhea (Fig. 2). An electrocardiogram and repeated studies of serum electrolytes (Table 1) were used as guides to replacement therapy (Table 2). Bacteriologic studies of the stools and casts were reported on the 6th day; all cultures were predominantly colonies of *Micrococcus pyogenes* (coagulase positive) and *Pseudomonas aeruginosa*. The staphylococci were sensitive to chloramphenicol and erythromycin. Chloramphenicol was therefore given intramuscularly in 500-mg. doses every 12 hours in addition to the intravenous administration of 500 mg. of erythromycin every 12 hours. In view of the possible dissemination of bacterial infection it was considered best to discontinue ACTH and cortisone. Clinically, there was little

FIGURE 1. *Appearance of the Colonies of Staphylococci in the Pseudomembrane (X 325).*

improvement except that the temperature fell to 101.9°F. On the following day the patient was mildly euphoric; the abdomen was less distended, and a semiformed stool was passed. The requirement for nor-epinephrine decreased, and the drug was discontinued entirely on the 9th postoperative day, 96 hours after onset of shock. Gastric aspiration by Levin tube yielded pseudomembranous casts similar to those passed in the stool.

On the 6th and 8th postoperative days the serum bilirubin was 15 and 14 mg. per 100 cc., and the cephalin flocculation was ++++ in 48 hours. The protein level, 7.5 gm. per 100 cc. before operation, had fallen to 4.3 gm., with 3 gm. of albumin and 1.3 gm. of globulin (Table 1). Human serum albumin, in 100-cc. doses, was administered intravenously over 24-hour periods. Slowly falling hemoglobin values were corrected by whole-blood transfusion.

The subsequent week was marked by intermittent episodes of watery diarrhea, lethargy and depression. The temperature fluctuated from 99.9 to 101.9°F. On the 14th postoperative day ACTH was again administered in dosages of 25 mg. intravenously over an 8-hour period each day for 5 days. A gradual improvement was noted. The patient began to eat more, and abdominal distention and peripheral edema decreased. A paroxysmal episode of hypertension (systolic pressure above 300) developed on the evening of the 14th postoperative day. Veriloid, 5.2 mg. per liter of 5 per cent glucose and water, was given intravenously at a rate titrated to maintain the systolic blood pressure below 220. It is interesting that urinary output had decreased during the 2

preceding days and that, on the day the hypertensive crisis occurred, pronounced diuresis started and persisted for the next 14 days.

After 5 days ACTH was discontinued. Within 2 days abdominal distention was again noted. The patient appeared confused and irrational at times. The clinical improvement noted earlier had regressed. ACTH, 25 mg. intravenously over an 8-hour period once a day, was started again on May 13 and continued for 7 days. During that week he ate solid food, was out of bed over increasingly prolonged periods and had only 2 or 3 formed or semiformed stools daily.

After the last dose of ACTH on May 20, approximately 1 month after surgery, 25 mg. of testosterone was given twice a week intramuscularly in an attempt to restore a positive nitrogen balance. Additional supportive measures consisted of large doses of multivitamins, forced feedings, repeated whole-blood transfusions and, empirically, a preparation of lactic acid bacilli (Lactinex). The liver-function tests gradually returned to a normal value, as did the total protein levels. On the 50th hospital day proctoscopy revealed mild edema and tiny focal linear ulcerations of the mucosa underlying small strips of pseudomembrane. A gastrointestinal series and small-bowel studies showed thickened, coarsened mucosal folds, with loss of the fine jejunal pattern. Six weeks after discharge sigmoidoscopic examination was negative, and the small-bowel pattern was completely normal.

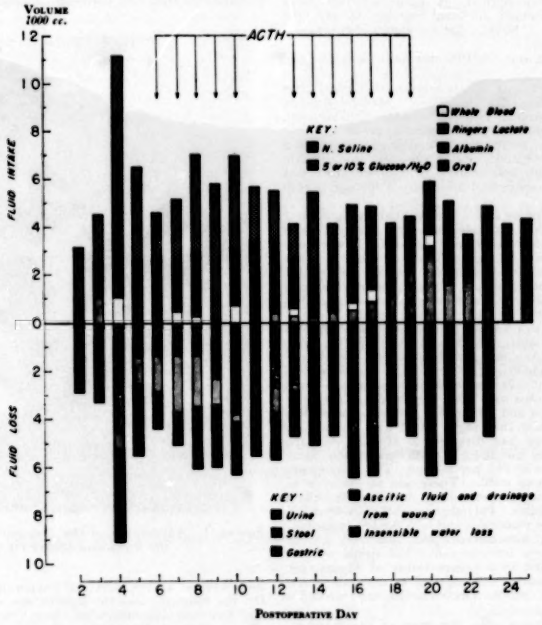


FIGURE 2. *Chart of Fluid Administered and Lost.*

## DISCUSSION

The occurrence of pseudomembranous enterocolitis as a complication of surgery has been attributed to the effects of the antibacterial drugs on the intestinal flora. However, Pettet et al.[3] have emphasized the fact that this is fallacious. In reviewing the case histories of 94 patients who died in the postoperative period with extensive pseudomembranous inflammation, they found that this syndrome had not become significantly more frequent in recent years.

It is of further interest that no case of pseudomembranous enterocolitis was encountered at the Brooklyn Veterans Administration Hospital during the four years that it had been open. Yet within a period of three weeks 2 proved cases were encountered on the same ward, suggesting that antibiotics play only a subsidiary role in the onset. It is possible that an enterotoxic strain of the staphylococcus was given uninhibited opportunity to exert its effects by the suppression of the other bacteria by antibiotics. The other possibility is that this acute necrotizing reaction is a hyperergic response of an organ sensitized to that particular bacterial allergen — a type of Shwartzman phenomenon.

The clinical appearance of the patient suggested that of patients with Asiatic cholera. Tissue dehydra-

tion, in spite of energetic fluid replacement, was striking. The treatment, therefore, was aligned to that used in the treatment of cholera. ACTH and cortisone were given in the first forty-eight hours, to diminish tissue exudation, in spite of the danger of bacterial dissemination. Erythromycin and chloramphenicol were used because it was believed that the improvement noted in the liver function suggested that the hepatic damage was related to the shock.

Renal changes also occur in this syndrome. Degenerative tubular changes have been described.[4] Urinary abnormalities, with casts and many red and white blood cells in the sediment and albuminuria, were noted frequently in the case reported above. The

TABLE 1. *Blood Changes in Pseudomembranous Enterocolitis.*

| Post-operative Day | Hemoglobin | Hematocrit | White-Cell Count | Carbon Dioxide | Chloride | Sodium | Potassium | Albumin | Globulin | Bilirubin | Cephalin Flocculation |
|---|---|---|---|---|---|---|---|---|---|---|---|
| | *gm./100 cc.* | % | *x10³* | *milli-equiv./liter* | *milli-equiv./liter* | *milli-equiv./liter* | *milli-equiv./liter* | *gm./100 cc.* | *gm./100 cc.* | *mg./100 cc.* | *per 48 hr.* |
| 2 | 14.4 | | | 17.3 | 113 | | | 4.8 | 2.6 | | |
| 3 | 13.1 | | | 25.4 | 108 | 141.0 | 4.8 | | | | |
| 4 | 13.0 | 43 | 5.7 | | | 136.0 | 4.6 | | | | |
| 5 | 16.8 | 53 | 25.8 | 21.8 | 102 | 129.0 | 4.6 | 3.0 | 1.3 | | |
| 6 | 16.9 | 51 | 21.1 | 13.3 | 102 | 120.5 | 4.3 | 3.5 | 0.8 | 15.9 | ++++ |
| 7 | 15.8 | 48 | 22.0 | 19.0 | 97 | 127.5 | 4.6 | 2.9 | 1.4 | 14.7 | |
| 8 | 12.8 | 45 | 12.0 | 17.0 | 107 | 125.8 | 4.4 | 3.2 | 1.9 | | |
| 9 | 11.6 | 39 | 9.1 | 19.0 | 99 | 124.5 | 4.5 | 4.1 | | 9.5 | |
| 10 | 10.3 | 36 | 5.4 | 25.3 | 94 | 128.0 | 3.7 | | | | |
| 11 | 12.6 | 40 | | 30.9 | 115 | 142.0 | 3.9 | | | | |
| 12 | 13.3 | 42 | | 29.9 | 120 | 135.5 | 6.2 | | | | |
| 13 | 12.8 | 40 | 13.3 | 25.3 | 113 | 127.5 | 5.3 | | | 3.9 | |
| 14 | 12.4 | 38 | | 17.0 | 115 | 130.0 | 5.0 | | | | |
| 15 | 10.6 | 37 | | 21.8 | 110 | 140.8 | 4.3 | | | | |
| 16 | 10.3 | 33 | | 21.8 | 105 | 135.7 | 4.1 | 3.3 | 1.8 | | |
| 17 | 9.7 | 34 | 19.5 | | 110 | 134.3 | 4.2 | | | | |
| 18 | 10.5 | 34 | 16.6 | 25.6 | 112 | | | | | | |
| 19 | | | | | | | | | | | |
| 20 | 11.0 | 37 | 23.0 | 22.3 | 111 | 143.7 | 3.6 | 3.2 | 1.9 | | |
| 21 | 12.8 | 43 | 17.0 | 22.0 | 110 | 135.0 | 4.3 | | | 7.3 | + |
| 22 | 13.5 | 43 | | | 102 | 140.8 | | | | | |
| 23 | | | | | | | | | | | |
| 24 | 11.3 | 37 | 16.2 | 29.0 | 106 | 137.5 | 3.1 | | | | |
| 25 | | | | | | | | | | | |
| 26 | | | | | | | | | | | |
| 27 | 11.6 | 37 | 33.0 | 25.4 | 105 | 141.5 | 3.9 | 3.6 | 2.2 | | |
| 28 | | | | | | | | | | 3.6 | ++ |
| 29 | | | | | | | | | | | |
| 30 | 12.8 | 44 | 30.0 | | | | | | | 0.6 | — |

staphylococci were sensitive to these agents. This was later confirmed by the sensitivity studies.

The elevated serum bilirubin and the evidence of hepatocellular damage in this patient have not been emphasized in other reports. Terplan et al.[4] found varying degrees of liver damage in 8 cases. The pathology varied from cloudy swelling and fat phanerosis to focal areas of central necrosis. The possibility that the liver damage was secondary to an ascending cholangiolitis was considered. The damaging effects of shock, severe dehydration and infection must have helped alter the physiology of the liver. The prompt blood urea nitrogen, however, remained at normal levels. The acute episode of hypertension can be explained by a sudden marshaling of the nor-epinephrine from the extracellular pool when fluid was mobilized after diuresis.

The clinical picture described by Prohaska, Govostis and Taubenhaus[5] differed so from the fulminating process reported by Childs and Beatty,[6] Terplan et al.[4] and others[2,7,8] that the suggestion has been made that these are two distinct entities. In our patient, certainly, during the early period of shock, we could not correlate the clinical picture to that in the cases of

Prohaska and his associates, in which shock did not develop and ACTH therapy was not begun until as long as twenty-one to thirty-five days after surgery. Having survived the initial fulminating phase of shock, however, our patient had a course that was

TABLE 2. *Electrolyte Solutions Administered.*

| Post-operative Day | 5% Solution of Sodium Bicarbonate | Ringer's Solution | Potassium Chloride |
|---|---|---|---|
| | *milliequiv./liter* | *cc.* | *milliequiv.* |
| 2 | — | — | 40 |
| 3 | — | — | 40 |
| 4 | — | 2000 | 60 |
| 5 | 44.6 | — | 60 |
| 6 | 223 | 1000 | 60 |
| 7 | 133.8 | — | 80 |
| 8 | 133.8 | 1000 | 60 |
| 9 | 267.6 | — | 80 |
| 10 | 89.2 | — | 140 |
| 11 | — | 1000 | 160 |
| 12 | — | 3000 | 100 |
| 13 | — | 2025 | 40 |
| 14 | 89.2 | 2000 | 40 |
| 15 | — | 1100 | 60 |
| 16 | — | 700 | 60 |
| 17 | — | 800 | 60 |
| 18 | — | 1500 | 60 |
| 19 | — | — | 60 |
| 20 | — | 1000 | 60 |
| 21 | — | 1000 | 60 |
| 22 | — | — | 60 |
| 23 | — | — | 60 |
| 24 | — | — | 60 |
| 25 | — | — | 60 |
| 26 | — | — | 60 |
| 27 | — | — | — |
| 28 | — | — | — |
| 29 | — | — | — |
| 30 | — | — | — |

quite similar. We therefore believe that this is one syndrome with varying degrees of severity, depending on such factors as virulence of the organism and host sensitization and responsiveness.

The energetic therapeutic regimen used in our patient can be outlined. The first stage of treatment consisted of the following measures:

The primary measure is *restoration of blood pressure to normal.* The mechanism of shock in these cases is not known. It has repeatedly been shown that replacement of fluid and electrolytes alone will not prevent death from shock. As seen frequently in fulminating peritonitis the toxicity of severe infection alone may cause shock by paralysis of the splanchnic capillary-arteriolar bed. Infection also perpetuates the shock of hypovolemia. Therefore, the administration of nor-epinephrine in adequate dosage to maintain systolic blood pressure is important. The amount of this drug needed will decrease after fluid loss has been replaced and infection controlled. The second step is *restoration of fluid and electrolyte losses.* In severe cases the measurable fluid losses may range from 10 to 20 liters. Despite such replacement in the case presented above, dehydration was evident. This appeared to be secondary to the massive amounts of fluid lost into the lumen of the intestines. The intravenous insertion of two large-bore polyethylene tubes was required to enable the administration of large quantities of fluid and maintain adequate flow of nor-epinephrine. Fluid and electrolyte replacement was best maintained by utilization of the previous eight-hour losses as a guide and by daily determinations of serum carbon dioxide, chloride, sodium and potassium. The third measure in this stage is *discontinuance of broad-spectrum antibiotics.* Erythromycin has been reported as the most effective drug against staphylococci, although a rapid increase in the number of strains resistant to this antibiotic is being noted. Therefore, even before specific bacteriologic data are at hand, erythromycin should be administered. Bacitracin should also be considered for use. Alterations in fecal bacteria should be followed by frequent stool cultures, and when an organism is isolated its sensitivity to the various antibiotics determined. The drug to which the bacteria are most vulnerable can then be given.

The second phase of treatment is concerned with supporting the patient during the reparative stage:

First of all, the great loss of protein requires repeated whole-blood transfusions and human serum albumin. Secondly, the caloric requirements can in part be met by the intravenous administration of 10 per cent dextrose or levulose until the patient is able to eat. As the result of the lethargy, mental confusion and physical exhaustion, which are noted in the early periods of convalescence, the ability of the patient to eat and co-operate in his treatment may be considerably impaired. Since ACTH induces euphoria and enhances the appetite, dramatic improvement may follow the use of ACTH, as was noted in the case presented.

The danger of disseminating infection may preclude the use of ACTH in the early phases, but ACTH can safely be administered when the infection has been controlled as evidenced by decreasing pyrexia and diminishing stool colony counts. The drug should be discontinued when clinical improvement permits. The alteration of the normal bacterial flora of the gastrointestinal tract during the

use of wide-spectrum antibiotics has been held responsible for the emergence of pathogenic staphylococci en masse. Restoration of the normal flora appears to be a reasonable procedure, therefore, and may be helped possibly by the use of any preparation containing lactobacillus. Finally, during the later period of convalescence, forced feedings of a high-calorie, high-protein diet with supplements of all the vitamins and crude liver extract will hasten recovery. The administration of testosterone has been reported as an aid in restoring positive nitrogen balance by improving anabolic processes.

## Summary

A patient who recovered from a postoperative staphylococcal enterocolitis after the onset of shock is described.

The relation of fulminating and subacute forms of pseudomembranous enterocolitis is discussed. The clinicopathological features encountered are elaborated.

Specific points of therapy and their indications are set forth.

We are indebted to Dr. Marvin Solomon for his co-operation in preparing the pathology slides and directing the bacteriologic studies used in this report.

## References

1. Finney, J. M. T. Gastroenterostomy for cicatrizing ulcer of pylorus. *Bull. Johns Hopkins Hosp.* 4:53, 1893.
2. Dearing, W. H., and Heilman, F. R. Micrococcic (staphylococcic) enteritis as complication of antibiotic therapy: its response to erythromycin. *Proc. Staff Meet., Mayo Clin.* 28:121-134, 1953.
3. Pettet, J. D., Baggenstoss, A. H., Dearing, W. H., and Judd, E. S., Jr. Postoperative pseudomembranous enterocolitis. *Surg., Gynec. & Obst.* 98:546-552, 1954.
4. Terplan, K., Paine, R. J., Sheffer, J., Egan, R., and Lonsky, H. Fulminating gastroenterocolitis caused by staphylococci: its apparent connection with antibiotic medication. *Gastroenterology* 24:476-509, 1953.
5. Prohaska, J. V., Govostis, M. S., and Taubenhaus, M. Postoperative pseudomembranous enterocolitis: successful treatment with corticotropin. *J.A.M.A.* 154:320-323, 1954.
6. Childs, S. B., and Beatty, E. C., Jr. Fatal enteritis: relation to antibiotic therapy. *Arch. Surg.* 68:486-490, 1954.
7. Fairlie, C. W., and Kendall, R. E. Fatal staphylococcus enteritis following penicillin and streptomycin therapy. *J.A.M.A.* 153:90-94, 1953.
8. Penner, A., and Bernheim, A. I. Acute postoperative enterocolitis: study of pathologic nature of shock. *Arch. Path.* 27:966-983, 1939.

# MANIFESTATIONS OF ACUTE LEUKEMIA IN THE PARENCHYMA OF THE LUNG*

Daniel J. Nathan, M.D.,† and Martin Sanders, M.D.‡

NEW YORK CITY

ACUTE leukemia is characterized histologically by infiltration of the bone marrow with immature hematic cells and a variable degree of similar invasion of the other tissues of the hematopoietic system. Occasionally, however, in unusual situations a sufficient degree of infiltration occurs in other organs so that the presenting symptoms and clinical picture are highlighted by these concomitant sites of involvement.

Infiltrations of the lung are not usually considered part of the clinical picture of acute leukemia. For this reason roentgenograms of the chest are not routinely taken in these cases, allowing this entity to go unrecognized. It is the purpose of this paper to review this subject in detail. A careful study of 59 autopsied cases of acute leukemia is made in an attempt to draw a clinicopathological correlation by means of an unusual case study.

## Review of the Literature

Although hilar lymphadenopathy and pleural effusion are frequently seen in cases of leukemia, the fact that the parenchyma of the lung may be involved is seldom appreciated. In the acute forms of leukemia this entity is apparently rare, as indicated by a careful search of the literature. The majority of the reports concern chronic leukemia (myelogenous and lymphatic), acute leukemia with lung involvement being described in isolated reports.

In very early pathological studies[1-3] before adequate tissue-staining technics were available, gross lesions in the lungs of patients succumbing to various types of leukemia were described as a probable manifestation of leukemic infiltration. It was not until 1931, when Fischer[4] made a careful histologic study of the pulmonary findings in leukemia, that this entity was clearly described. In a group of 32 autopsied cases he reported the presence of miliary lesions in the lung due to leukemic infiltration. Fischer doubted if the earlier reports actually were bona-fide leukemic infiltrates because he was unable to find any large tumoral masses in his material.

The first paper dealing with this subject to appear in the American literature was a case study by Joachim and Loewe,[5] who presented a case of acute myelogenous leukemia characterized by migratory infiltrations of both lungs that at autopsy were ascribed to "repeated infarctions secondary to vascular occlusions with myeloid cells." Fiessinger and Fauvet[6] attached similar significance to the process of vascular occlusion. In a patient who succumbed to chronic myelogenous leukemia they found numerous vessels, 3 or 4 mm. in size, completely occluded by white thrombi made up of leukemic cells. In addition,

*From the departments of Hematology and Internal Medicine, Mount Sinai Hospital.

†Assistant to the director of medical education and fellow in medicine, Beth-El Hospital, Brooklyn, New York; formerly, assistant resident in medicine, Mount Sinai Hospital.

‡Assistant resident in medicine, Beth Israel Hospital, Boston; formerly, assistant resident in medicine, Mount Sinai Hospital.

x-ray study of the chest revealed many small, round cavities in both lung fields. These cavities at autopsy consisted of nodular aggregations of leukemic cells with central liquification attributed to the release of proteolytic enzymes by the degenerating white cells. Nowhere did these lesions communicate with the bronchioles.

Schinz et al.[7] describe a case of acute myelogenous leukemia in which x-ray examination disclosed "a close-meshed reticular pattern of shadows in both middle and lower lung fields and a mottled clouding of the right lower lung field." At autopsy the lung structure was densely infiltrated with abnormal leukocytes. In another patient with acute leukemia Clement and Gormezano[8] report the finding of diffuse miliary nodules on x-ray study, attributed to variable leukemic infiltration of the alveolar septums at autopsy. Rabin[9] mentions a leukemic patient with miliary lesions of the lung that closely resembled Boeck's sarcoid.

In an interesting report of a case of acute leukemia and another of chronic lymphatic leukemia, Devic, Pommateau and Ducreux[10] observed striking resolution of nodular and linear pulmonary infiltrations on cortisone therapy.

In a roentgenographic study of 48 patients with chronic lymphatic leukemia Kirklin and Hefke[11] found 4 patients (8.3 per cent) with pulmonary infiltrations that were ascribed to the underlying disease. Vieta and Craver,[12] on the other hand, in a series of 158 cases of the same disease, reported positive x-ray findings in 24.6 per cent. In another 1.9 per cent isolated nodules occurred. Autopsy in 31 of these cases revealed parenchymal involvement of the lung in 19 per cent. Falconer and Leonard,[13] in a similar study, found a frequency of 30 per cent at autopsy.

Pulmonary infiltrations, as observed roentgenographically, are much less common in myelogenous than in lymphatic leukemia. In a study of 52 cases of all types of myelogenous leukemia Vieta and Craver[12] observed infiltrations in 7.6 per cent; isolated nodules were not seen in any case. In general, the appearance was that of miliary foci. At autopsy, however, the rate of pulmonary infiltrations was 13 per cent. Apparently, the infiltrations are often microscopic and are not appreciated clinically.

TABLE 1. *Summary of 14 Cases with Leukemic Infiltrations of the Lung.*

| Case No. | Sex | Age yr. | Hematologic Findings | Microscopical Findings in Lungs |
|---|---|---|---|---|
| 1 | F | 64 | Peripheral white-cell count of 75,000, with 88% blast cells; bone marrow contained 94% blast cells. | Variable degree of leukemic infiltration of alveolar septums |
| 2 | M | 64 | Peripheral white-cell count of 102,000, with 87% blast cells; bone marrow showed marked increase in blast cells. | Small infiltrations of leukemic cells next to bronchioles |
| 3 | F | 19 | Peripheral white-cell count of 4400, with 38% blast cells; bone marrow contained 93% blast cells. | Most alveoli filled with fibrin & red cells; many alveolar walls contained leukemic cells. |
| 4 | M | 55 | Patient died before any study could be made | Focal areas of septal infiltration by leukemic cells |
| 5 | F | 50 | Peripheral white-cell count of 160,000, with 87% blast cells; bone marrow showed marked increase in blast cells. | Small infiltrations of leukemic cells next to bronchioles |
| 6 | M | 35 | Patient died before any study could be made | Many alveolar walls contained leukemic cells; nests of leukemic cells near bronchioles. |
| 7 | F | 32 | Peripheral white-cell count of 111,000, with 4% blast cells; bone marrow not examined. | Small perivascular areas of leukemic infiltration |
| 8 | F | 2½ | Peripheral white-cell count of 62,000, with 79% blast cells; bone marrow contained 100% blast cells. | Dense aggregations of leukemic cells subpleurally, with fibrotic reaction of pleura. |
| 9 | M | 3 | Peripheral white-cell count of 130,000, with 96% blast cells; bone marrow contained 84% blast cells. | Moderate degree of leukemic infiltration of alveolar septums in focal areas |
| 10 | F | 50 | Peripheral white-cell count of 260,000, with 66% blast cells; bone marrow not examined. | Small collections of leukemic cells around bronchioles & small blood vessels; scattered areas of septal infiltration. |
| 11 | M | 42 | Peripheral white-cell count of 123,000, with 95% blast cells; bone marrow contained 100% blast cells. | Focal collections of leukemic cells subpleurally |
| 12 | F | 8 | Peripheral white-cell count of 12,500, with 59% blast cells; bone marrow contained 85% blast cells. | Slight leukemic infiltration of alveolar septums |
| 13 | M | 34 | Peripheral white-cell count of 2400, with 9% blast cells; bone marrow contained 100% blast cells. | Focal areas of leukemic infiltration of alveolar septums |
| 14 | M | 28 | Peripheral white-cell count of 50,000, with 25% blast cells; bone marrow contained 31% blast cells. | Focal collections of leukemic cells in alveolar septums |

## Case Material

In this study we reviewed a total of 59 consecutive autopsied cases of acute leukemia from the post-mortem records of the Mount Sinai Hospital from January, 1946 to May, 1954. The diagnosis in each case was made clinically according to recognized criteria and established pathologically. Patients in whom acute leukemia developed in the spent phase of polycythemia vera and those manifesting a terminal blastic exacerbation of chronic myelogenous leukemia were not included. No attempt was made to identify the possible lymphogenous, myelogenous or monocytic origin of the predominating blast-cell type.

A careful review of the autopsied material indicated 14 cases (23.7 per cent) with definite leukemic involvement of the pulmonary parenchyma (Table 1). We were careful to include only the specimens of the lung in which the leukemic cells were not confined to the lumens of the blood vessels.

In general the infiltrations occurred at three sites. The most common and perhaps the most clinically

significant finding, as pointed out below, was a variable degree of invasion of the walls of the alveolar septums (Fig. 1). Here, the cellular aggregates on occasion could be seen as dense infiltrations compressing the capillaries and, at times, the alveoli themselves. Unless there was an associated bronchopneumonia no leukemic cells could be seen in the lumens of the alveoli. In general, septal invasion appeared to be a focal process, with miliary nodules of leukemic tissue seen gradually merging with normal alveolar septums a few millimeters away.

Focal collections of leukemic cells around or adjoining small bronchioles and blood vessels were the second most common site (Fig. 2). Here, the lesions occurred as small nests of densely packed young white cells. Although at times the walls of the bronchioles and blood vessels revealed a slight degree of cellular

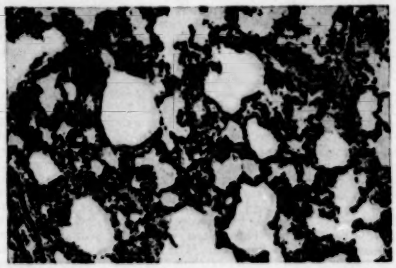

FIGURE 1. *Section of the Lung, Showing a Variable Degree of Leukemic Infiltration of the Alveolar Septums (X70).*

infiltration, there was no encroachment on the lumens of these structures.

Finally, as a less frequent occurrence, there was a variable degree of focal cellular infiltration located subpleurally (Fig. 3).

In no case were we able to find vascular occlusions by leukemic cells with resultant pulmonary infarction such as that described by Joachim and Loewe[5] and Fiessinger and Fauvet.[6] Large, isolated nodules were also absent.

The material was examined to determine the possibility of correlation between the degree of leukocythemia or leukopenia and the presence of pulmonary infiltration. Table 1 indicates the presence of infiltrations in the alveolar septums in cases with either very low or very high white-cell counts (Cases 10 and 13). In addition, in the remainder of the material in which pulmonary infiltrations were not found at autopsy, all varieties of white-cell levels in the peripheral blood were found. There appears to have been no correlation between the level of the white-cell count and the presence or absence of leukemic pulmonary infiltrations.

## CLINICOPATHOLOGICAL CORRELATION

Respiratory symptoms in this group of 14 patients were absent in almost all cases. When present they were usually observed just before death and could be attributed to pulmonary edema, or the air hunger of severe anemia and hyperpyrexia.

Since there was no tendency for the lumens of the bronchioles to become obstructed by leukemic inva-

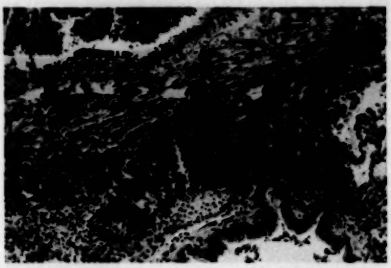

FIGURE 2. *Densely Packed Nest of Leukemic Cells Situated between a Small Bronchiole and an Artery (X70).*

sion, signs of obstructive emphysema (wheezing and prolonged expiration) did not occur.

Pleuritic pain and signs of a pleural effusion were present (Case 8) and could be seen to be due to sub-

FIGURE 3. *Section through the Visceral Pleura, Revealing an Organizing Fibrotic Reaction, with Dense Leukemic Infiltration (X70).*

pleural leukemic infiltrations, with resultant irritation of the pleura (Fig. 3).

It is not altogether surprising that x-ray examination of the chest was negative in most cases. Except for the presence of a pleural effusion on the right in Case 8 the positive x-ray findings were attributed to disease in the lung other than leukemia. The fact that the pulmonary infiltrations noted at autopsy were mainly of microscopic size is consistent with the almost regular negative roentgenologic examinations of the chest.

The most frequent form of leukemic infiltration of the lung (Fig. 1) showed that the abnormal cells were crowded into the alveolar septums widely separating the blood capillaries from the alveolar walls. It is highly probable, as evidenced by the reports above,[5-10] that progression and extension of this process might lead to lesions grossly visible at autopsy, a miliary distribution of lesions seen roentgenographically and serious impairment of pulmonary function. This brings to mind a physiopathologic disturbance

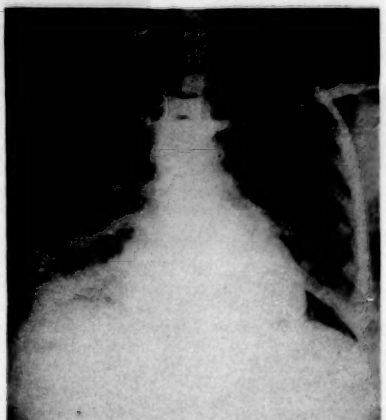

FIGURE 4. *X-Ray Film Taken on the Second Hospital Day, Revealing Fine, Diffusely Dispersed Infiltrations throughout Both Lung Fields.*
*At the right base these densities appear to be confluent.*

described by Austrian et al.[14] in a group of patients with unusual diseases of the lung. These authors described a series of patients who manifested hyperventilation and cyanosis, widely dispersed, fine pulmonary infiltrations on x-ray examination and widening of the alveolar septums by various types of pathologic processes on histologic study. They postulated the defect to be one of impaired oxygen diffusion across the diseased alveolar membrane and called this mechanism "alveolar-capillary block." As examples they cited the following diseases: Boeck's sarcoid, beryllium granulomatosis, scleroderma and pulmonary granulomatosis of unknown etiology. They also stated that this mechanism probably occurred in the Hamman–Rich type of fibrosing interstitial pneumonitis, miliary tuberculosis, lymphangitic carcinosis, amyloidosis, asbestosis and xanthomatosis — all processes characterized by a protracted course of pulmonary insufficiency that in most cases proceeds slowly to a fatal outcome.

In the case reported below, a roentgenographic and clinical picture suggesting the syndrome of "alveolar-capillary block" developed during the course of acute leukemia. Although we are unable to present autopsy findings in this case, the sequence of events as they materialized was quite striking and may serve as considerable stimulation to those interested in this subject.

## CASE REPORT

V. R., a 20-year-old woman, was admitted to Mount Sinai Hospital on October 7, 1953, complaining of severe shortness of breath. She had been well until 2 weeks previously, when chilly sensations, easy fatigability and fever developed. She was treated for "pyelitis" with bed rest, oxytetracycline and penicillin. Although urine samples cleared on antibiotic therapy the temperature continued to rise, and she was admitted to another hospital, where a smear of the peripheral blood and bone marrow was reported as showing changes compatible with acute leukemia. On the 3d day severe dyspnea, tachypnea and cyanosis developed, and she was transferred to Mount Sinai Hospital.

The most striking observation noted on physical examination was the extraordinary amount of respiratory distress. The patient was sitting upright in bed, hunched slightly forward. She was extremely dyspneic and cyanotic. She did not cough but was pale and perspiring. Large, flame-shaped hemorrhages were visible in both ocular fundi. Small anterior cervical, axillary and inguinal lymph nodes were palpable. There were no abnormal findings in the chest. Examination of the heart revealed a sinus tachycardia. There were no murmurs and no clinical evidence of cardiac enlargement. The neck veins were not distended. The liver was not palpable. The spleen was easily palpable 3 cm. below the left costal margin. The hepatojugular reflux was not present. Neurologic examination was negative. There was no evidence of congestive heart failure.

The temperature was 105°F. by rectum, the pulse 120, and the respirations 60. The blood pressure was 120/70.

Examination of the blood disclosed a red-cell count of 3,030,000, with a hemoglobin of 9 gm. per 100 cc. and a white-cell count of 9800, with 14 per cent lymphocytes, 2 per cent band forms, 2 per cent segmented neutrophils, 14 per cent promyelocytes and 68 per cent myeloblasts. The platelets were 42,000. Examination of the bone marrow revealed 65 per cent myeloblasts, 18 per cent promyelocytes, 4 per cent lymphocytes, 11 per cent reticulum cells and 2 per cent normoblasts. The blood picture was considered to be typical of acute myelogenous leukemia. The direct Coombs test was negative. Urinalyses were unremarkable except for a + to ++ test for albumin and microscopical evidence of hematuria. An electrocardiogram was within normal limits. An x-ray film of the chest taken on October 8 revealed fine, lacy infiltrations distributed throughout most of both lung fields. At the right base there was a suggestion of some confluence of these densities. The cardiac shadow was normal (Fig. 4).

Despite large doses of erythromycin, penicillin, streptomycin and cortisone and oxygen therapy, fever and severe respiratory distress continued. The lung fields remained free from physical findings. On the 6th hospital day Amethopterin, 5 mg. daily, was started. Over the next 10 days the respiratory distress, tachypnea and apprehension progressively lessened. By the 16th day oxygen was discontinued, without cyanosis or dyspnea. The respiratory rate fell to 20. Coincident with this was a fall in temperature to 101°F. The peripheral blood picture at this time revealed a red-cell count of 2,500,000, with a hemoglobin of 7.1 gm. per 100 cc., and a white-cell count of 1000, with 7 per cent band forms, 18 per cent segmented neutrophils, 73 per cent lymphocytes and 2 per cent myeloblasts. Platelets numbered 6000. Differential study of the bone marrow disclosed 26

per cent myeloblasts, 4 per cent promyelocytes, 8 per cent band and 6 per cent segmented forms, 36 per cent lymphocytes and 10 per cent normoblasts. A repeat film taken on October 22 showed some resolution of the miliary infiltrations. By the 26th hospital day the patient had become afebrile. The platelets count began to increase, and blast forms disappeared from the peripheral blood. Amethopterin was discontinued.

A repeat film of the chest taken on November 5 revealed complete clearing of both lung fields (Fig. 5). Blood studies disclosed a red-cell count of 4,100,000, with a hemoglobin of 11.4 gm. per 100 cc., and a white-cell count of 2900, with a normal differential; the platelets had increased to 110,000. Bone-marrow aspiration demonstrated moderate

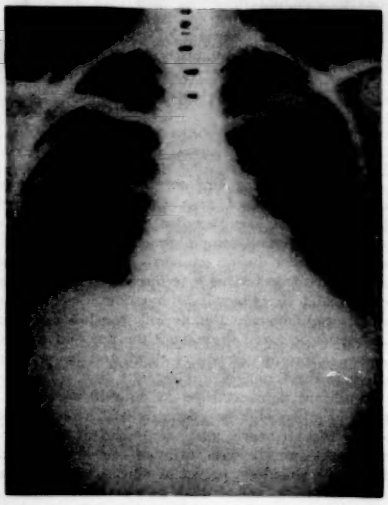

FIGURE 5. *X-Ray Film Taken a Month Later, Showing Complete Resolution of All Pulmonary Infiltrations.*

hypocellularity, the predominant cell continuing to be the myeloblast.

The patient was discharged from the hospital asymptomatic on November 11. She was maintained on Amethopterin, 5 mg. daily. At follow-up study on December 10 she was free from symptoms and had a completely normal peripheral blood and bone marrow, except for a total white-cell count of 2850. When seen again on January 12, 1954, she was complaining of fatigue and anorexia. Physical examination showed the reappearance of hepatosplenomegaly and generalized small lymph nodes. Myeloblasts had reappeared in the peripheral blood, and the dosage of Amethopterin was increased to 7.5 mg. daily. While she was in another community a massive gastrointestinal hemorrhage suddenly developed, and she died on January 27. No postmortem examination was performed.

## DISCUSSION

When this patient was first seen the predominating feature was that of severe respiratory difficulty as manifested by marked hyperventilation and moderate cyanosis. This was especially striking in the absence of any evidence for airway obstruction and a completely clear chest on physical examination. Except for the presence of cyanosis, the hyperventilation would probably have been considered to be on a hysterical basis. Accordingly, an x-ray film of the chest was taken and revealed the appearance of widely dispersed miliary lesions. This brought to mind a number of pulmonary diseases described by Austrian et al.[14] Because of the nature of pulmonary involvement in leukemia and the potential development of a clinical condition of "alveolar-capillary block" as described in other disease states, the possibility of this entity was considered. Subsequently, with the complete clearing of respiratory symptoms and x-ray findings on Amethopterin therapy coincident with a remarkable hematologic remission, after massive doses of antibiotics had been ineffective, we came to the conclusion that in all probability the pulmonary process was leukemic in origin.

## SUMMARY AND CONCLUSIONS

Leukemic infiltration of the lung occurs in acute leukemia. A rate of 23.7 per cent was found in a series of 59 autopsied cases. The characteristic sites in the lung are described and illustrated. From a study of the histopathology and the case material a clinicopathological correlation is attempted. That leukemic infiltrations of the lung may be responsible for the syndrome of "alveolar-capillary block" is suggested by the presentation of an unusual case.

We are indebted to Drs. Daniel Stats and Louis R. Wasserman for their many helpful suggestions in the preparation of this manuscript, and to Mr. George Ozaki, who prepared the photomicrographs.

## REFERENCES

1. Boettcher, A. Zur pathologischen Anatomie der Lungen und des Darms bei Leukämie. *Virchows Arch. f. path. Anat.* 37:163-174, 1866.
2. Orth, J. *Lehrbuch der speciellen pathologischen Anatomie.* Vol. 1. 1014 pp. Berlin: Hirschwald, 1887. P. 482.
3. Rindfleisch, E. Fibroma pulmonum multiplex. *Virchows Arch. f. path. Anat.* 81:516-520, 1880.
4. Fischer, W. Die Gewächse der Lunge und des Brustfells. In *Handbuch der speciellen Anatomie und Histologie.* Edited by F. Henke and O. Lubarsch. Vol. III/3. 701 pp. Berlin: Springer, 1931. Pp. 509-606.
5. Joachim, H., and Loewe, L. Atypical acute myeloid leukemia with unusual pulmonary manifestations: case report with necropsy findings. *Am. J. M. Sc.* 174:215-225, 1927.
6. Fiessinger, N., and Fauvet, J. Le poumon leucémique. *Presse méd.* 49:449-451, 1941.
7. Schinz, H. R., et al. *Roentgen Diagnostics.* Vol. 3. *Thorax.* New York: Grune & Stratton, 1953. P. 2503 (Fig. 3253).
8. Clement, R., and Germezano, R. Leucémie aiguë à forme pulmonaire chez une fillette de 3 ans. *Presse méd.* 54:446, 1946.
9. Rabin, C. In Golden, R. *Diagnostic Radiology.* 2 vol. Baltimore: Williams & Wilkins, 1952. Vol. 1. P. 1820.
10. Devic, M., Pommateau, E., and Ducreux, P. Infiltrats pulmonaires au cours des leucoses: à propos de deux observations. *Lyon méd.* 189:198-204, 1953.
11. Kirklin, B. R., and Hefke, H. W. Roentgenologic study of intrathoracic lymphoblastoma. *Am. J. Roentgenol.* 28:681-690, 1951.
12. Vieta, J. O., and Craver, L. F. Intrathoracic manifestations of lymphomatoid diseases. *Radiology* 37:138-158, 1941.
13. Falconer, E. H., and Leonard, M. E. Pulmonary involvement in lymphosarcoma and lymphatic leukemia. *Am. J. M. Sc.* 195:294-301, 1938.
14. Austrian, R., et al. Clinical and physiologic features of some types of pulmonary disease with impairment of alveolar-capillary diffusion: syndrome of "alveolar-capillary block." *Am. J. Med.* 11:667-685, 1951.

# ACHLORHYDRIA

## Associated Symptoms and Response to Hydrochloric Acid

EMANUEL M. RAPPAPORT, M.D.*

JAMAICA, NEW YORK

CLINICAL entities that are at times associated with achlorhydria command the attention not only of the gastroenterologist but also of the internist, the hematologist and the dermatologist. Invariably present in pernicious anemia, gastric anacidity is encountered in gastritis of all types, as well as in gastric carcinoma and sprue. It has been reported a frequent finding in microcytic anemia,[1,2] hyperthyroidism[3] and chronic arthritis.[4] For many years dilute hydrochloric acid has been employed in various dermatologic disorders, particularly acne rosacea, and more recently it has been recommended for urticaria.[5]

The gastroenterologist occasionally encounters patients who have been taking dilute hydrochloric acid for prolonged periods with apparent symptomatic benefit, the medication having been prescribed without preliminary gastric analysis for a wide variety of dyspeptic symptoms, for diarrhea of undetermined origin or as adjunct therapy for anemia. In some of these cases subsequent studies show normal gastric secretions, and in others with proved achlorhydria the dose of acid used is so far below a therapeutic level as to discount the likelihood that any benefit was derived from the medication.

It is the purpose of this communication to survey the gastrointestinal symptoms associated with proved cases of achlorhydria and to evaluate their response to adequate doses of hydrochloric acid.

### MATERIAL

This series comprises 64 private patients with histamine-fast anacidity and is limited to those who were observed intermittently for periods ranging from six months to eight years. The test meal employed was 200 cc. of 7 per cent alcohol followed immediately by a subcutaneous injection of 0.5 mg. of histamine. Extractions were tested every fifteen minutes for two hours with Töpfer's solution. Fifty-two patients had 2 gastric analyses during their initial study and another during the subsequent three-month interval. Forty-two had 4 or more analyses. Only 1 test was done in 12 patients in whom the presence of achlorhydria had previously been established. Studies of the gastric enzymes were not done.

Cases in which x-ray examination demonstrated lesions of the gall bladder or gastrointestinal tract that might account for the symptoms and those of pernicious anemia or previous gastrectomy have been excluded from consideration. Included in this series are 2 women who underwent gastric polypectomy six years ago, and a man with a healed gastric ulcer in whom achlorhydria subsequently developed and who had been observed periodically for five years since then. In all cases of diarrhea appropriate studies were done to rule out infectious agents as an etiologic cause.

Thirty-six patients were males, and 28 were females. The age and sex distribution are indicated in Table 1. The youngest patient was twenty-one, and the oldest seventy-four years old when achlorhydria was first discovered.

### SYMPTOMS

Although the symptoms were by no means limited to the gastrointestinal tract, only those referable to that system have been recorded here (Table 2). The commonest primary complaint was epigastric distress occurring either during or shortly after meals, which 22 patients described as a feeling of fullness or distention, and 16 as burning discomfort. Belching was equally common and usually followed meals, but in 12 cases it occurred throughout the day and was explosive, affording temporary relief and being characteristic of aerophagia.

Significant pain occurred in only 10 cases. In 2 it was ulcerlike, with occasional relief by food or antacids although nearly all patients had at some time employed antacids with transient relief. Five patients had moderate, persistent epigastric pain unrelated to meals, and 1 had severe pain simulating biliary colic recurring daily for weeks. Two patients with normal electrocardiograms had precordial pain after meals that was relieved by belching. In no case did the pain awaken the patient from sleep.

Heartburn, a frequent symptom in functional dyspepsia, was present in only 9 cases. In addition to the almost invariable intolerance for spiced or fried foods indigestion was provoked in 16 cases by specific food groups. Five patients were unable to tolerate eggs or butter, as in biliary-tract disease. Five were distressed by milk or cheese, 3 could not eat "sweet" foods, and 3 had an aversion to meats. Persistent nausea, burning tongue without visible cheilitis, metallic taste, furred tongue and bad breath were occasional complaints. Vomiting was uncommon, although 1 woman reported that she had vomited after every meal for forty-two years, and a man stated that he had regurgitated bile an hour after each meal for more than twenty years. One patient was referred because of flatulence and urticaria.

Constipation requiring frequent laxatives or enemas, although infrequently the primary cause for investi-

*Associate physician and physician-in-charge, Gastrointestinal Outpatient Department, Queens General Hospital; associate physician (gastroenterology), Mary Immaculate Hospital.

gation, was an associated complaint in 38 cases. In 13 cases diarrhea was the primary symptom that initiated studies. In 7 patients the diarrhea occurred daily and was accompanied by cramps in the lower abdomen, without organic findings, as in the spastic-colon syndrome. In 6 patients the diarrhea was intermittent and attended by little abdominal distress. The youngest patient with diarrhea was a forty-two-year-old woman with an eighteen-month history of cramps and loose stools. All patients with diarrhea had been treated with the sulfonamides or antibiotics, with little benefit before their referral for study.

During the initial period of study 5 patients complained of anorexia and weight loss that was sufficiently pronounced to simulate an intra-abdominal cancer. One of them was subsequently subjected to an exploratory laparotomy elsewhere, with negative findings.

Although there was a noteworthy absence of uniformity or specificity of complaints the over-all clinical picture was one of long-standing digestive difficulties, usually with a distinctly functional and occasionally bizarre pattern. The onset or exacerbation of complaints frequently followed emotional stress, and nearly all symptoms were subject to unaccountable periods of remission. Occasionally, the symptoms were initiated acutely. Thus, explosive belching started in 2 men during their convalescence from coronary thrombosis, whereas in 4 others mild symptoms developed when new dentures were being fitted and they were unable to masticate their food. Upper respiratory infections were occasionally followed by protracted periods of digestive difficulties in patients with known achlorhydria.

TABLE 1. *Age and Sex Distribution in 64 Cases of Achlorhydria.*

| AGE | MALE PATIENTS | FEMALE PATIENTS |
|---|---|---|
| yr. | | |
| 20-29 | 2 | 1 |
| 30-39 | 1 | 3 |
| 40-49 | 9 | 4 |
| 50-59 | 13 | 9 |
| 60-69 | 7 | 7 |
| 70-79 | 4 | 4 |
| Totals | 36 | 28 |

## X-RAY STUDIES

An accurate estimate of gastric and small-intestine motility was not obtained in each case since the routine gastrointestinal series included only a single film taken three hours after the ingestion of barium. However, serial x-ray films of the small intestine were obtained in each of the 13 cases with diarrhea, with no striking degrees of gastric or small-intestine hypermotility. There was little difference in the progress of barium after three hours in patients with constipation and those with diarrhea. Indeed, the most rapid progress of barium occurred in a woman with constipation, barium reaching the sigmoid within three hours but remaining in the colon for several days.

## HEMATOLOGIC FINDINGS

Complete blood counts were done in each patient during the initial study, and in 61 the hemoglobin exceeded 80 per cent (Sahli) and the red-cell count 4,000,000. A mild secondary anemia was found in 3 women, the hemoglobin ranging from 60 to 65 per cent (Sahli) and the red-cell count from 3,400,000 to 3,600,000; a normal blood count was established by oral hematinics in each case, but in 2 anemia recurred during periods of observation exceeding six years.

TABLE 2. *Analysis of Symptoms Associated with Achlorhydria and Their Response to Dilute Hydrochloric Acid.*

| SYMPTOM | NO. OF CASES | PATIENTS WITH GOOD RESPONSE TO HYDROCHLORIC ACID | PATIENTS WITH NO RESPONSE TO HYDROCHLORIC ACID |
|---|---|---|---|
| Epigastric fullness | 22 | 5 | 17 |
| Epigastric burning | 16 | 2 | 14 |
| Flatulence | 25 | 6 | 19 |
| Explosive belching | 12 | 0 | 12 |
| Heartburn | 9 | 0 | 9 |
| Nausea | 9 | 0 | 9 |
| Vomiting | 6 | 0 | 6 |
| Food intolerance | 16 | 0 | 16 |
| Fats | 5 | 0 | 5 |
| Milk | 5 | 0 | 5 |
| "Sweets" | 3 | 0 | 3 |
| Meats | 3 | 0 | 3 |
| Pain | 10 | 1 | 9 |
| Ulcerlike | 2 | 0 | 2 |
| Precordial | 2 | 0 | 2 |
| Epigastric | 5 | 0 | 5 |
| "Biliary colic" | 1 | 0 | 1 |
| Anorexia | 5 | 0 | 5 |
| Weight loss | 5 | 0 | 5 |
| Constipation | 38 | 0 | 38 |
| Diarrhea | 13 | 1 | 12 |
| Bad breath | 4 | 0 | 4 |
| Burning tongue | 3 | 0 | 3 |
| Metallic taste | 2 | 0 | 2 |
| Urticaria | 1 | 1 | — |

## GASTROSCOPIC FINDINGS

Gastroscopy was done 40 times in 32 patients. Generalized mucosal atrophy was found in 9 patients, all over fifty-five years of age. Patchy atrophic gastritis occurred in 6, chronic superficial gastritis in 7, and hypertrophic gastritis in 5. Both patients from whom

polyps were removed had hypertrophic gastritis. In 5 cases the mucosa appeared normal. Gastroscopy was performed 3 times in the youngest patient, a twenty-one-year-old man, and chronic superficial gastritis was found, but a subsequent gastroscopic biopsy done elsewhere was reported as showing atrophic gastritis. In the older patients the mucosa appeared a dull greenish gray, with prominent submucosal vessels and little suggestion of inflammatory change, and thus the term "gastritis" hardly appeared applicable.

### Response to Therapy

Dilute hydrochloric acid was prescribed in doses of 30 drops in 120 cc. of sweetened water or fruit juice with each meal and increased to 1 or 2 teaspoonfuls if the smaller dose did not prove effective. Twelve patients found that the acid either caused or exacerbated epigastric burning, and Acidulin (glutamic acid hydrochloride) capsules were substituted. One capsule was taken before, and 2 with, and 1 after meals. All patients were placed on bland, low-residue diets, and in some cases vitamins were prescribed.

Relatively few patients in this series continued on hydrochloric acid for prolonged periods since in most of them the medication did not relieve the primary complaints after an adequate trial. In others, who experienced initial benefit, acid therapy proved of little value during subsequent recurrences of symptoms.

The response of the various symptoms to acid therapy is indicated in Table 2. Apart from the relief of relatively minor complaints of a sense of fullness after meals few long-term symptomatic benefits were derived from this type of medication, nor did the addition of pepsin and pancreatic extracts enhance the therapeutic merits of the hydrochloric acid.

One patient with nausea and severe epigastric pain obtained dramatic relief of symptoms initially, but during subsequent recurrences of symptoms acid therapy proved of little avail. Another patient, a seventy-two-year-old woman, noted rapid cessation of flatulence and urticaria; she had obtained good results from acid for the same symptoms eight years before. However, in not a single case was heartburn, constipation, anorexia or explosive belching appreciably altered by acid therapy, nor did any patient report an increase in tolerance to food groups that had previously caused distress. In 2 of the 3 women with anemia recurrent anemia of a hypochromic type developed under prolonged acid therapy.

Although acid substitution relieved diarrhea in only 1 case, this symptom was eventually controlled in 11 cases by various dietary changes with sedation and Metamucil, and in 1 it subsided spontaneously.

The 5 patients whose initial clinical picture simulated intra-abdominal neoplasm were observed for more than four years. None benefited from the acid although all were maintained on it for long periods. All experienced recurrence of symptoms after emotional disturbances, and 1 suffered prolonged periods of gastric distress after upper respiratory infections.

The least favorable results were obtained in patients with numerous complaints of many years' duration, and in those with marked neurotic components such as aerophagia. However, it is questionable whether the addition of acid was of appreciable benefit to patients who reported relief since similar beneficial results were obtained in patients who were unable to tolerate the acid or who discontinued this medication, relying entirely on diet, sedation and attention to adequate colonic evacuation.

The inefficacy of hydrochloric acid for the control of the symptoms associated with achlorhydria is apparent only if the patient is observed over a long period, since many of those who obtain initial relief of symptoms later have recurrences even while maintaining the prescribed dose of acid. It is thus difficult to evaluate properly the effect of any drug in the treatment of symptoms that are prone to spontaneous remissions.

### Discussion

Before the general use of histamine in gastric analysis, achlorhydria was believed to be a relatively common condition, and much emphasis was placed on the absence of acid as a primary cause of gastrointestinal symptoms and as an associated factor in many extra-intestinal clinical entities. Since the presence of achlorhydria is no longer accepted unless a potent parietal-cell stimulant is employed in gastric analysis, it has become apparent that true achlorhydria is quite uncommon before the fifth decade of life.

Gastric hydrochloric acid helps the digestion of proteins by pepsin, indirectly facilitates the liberation of iron from food, aids in the conversion of ferric to ferrous salts and possesses a possible bactericidal action in the stomach. It would be imagined that in the absence of free hydrochloric acid symptoms would of necessity arise in the course of these processes.

However, although achlorhydria probably does not occur in a normal stomach, its presence is not necessarily associated with symptoms. Thus, Rafsky and Weingarten[6] found achlorhydria in 17 per cent of asymptomatic persons above the age of sixty-five years. Furthermore, the low rate of achlorhydria in patients with functional gastrointestinal complaints is indicated by its presence in only 69 (1.2 per cent) of 5585 consecutive patients attending the Gastro-Intestinal Clinic at Mount Sinai Hospital, excluding those with well defined clinical entities usually associated with achlorhydria.[7]

Whereas it might be assumed that the absence of acid would prevent the proper digestion of proteins, tryptic activity in the small intestine is so efficient that digestion of meats is unimpaired in achlorhydria or after gastric resection. Thus, aversion to meats must be considered an individual idiosyncrasy unrelated to the gastric secretory potential.

Hydrochloric acid has been often used as adjunct therapy in hypochromic anemias since iron is more readily absorbed from an acid than an alkaline medium and insoluble iron compounds are formed in the small intestine when the pH is higher than 5.0. However, since the duodenal contents of persons with normal gastric secretions is almost neutral and the pH usually between 5 and 6, gastric hydrochloric acid has little effect on the reaction of the contents of the jejunum and the small doses of acid believed to assist in iron therapy are probably quite valueless. No significant differences in the red-cell count, hemoglobin or hematocrit have been found in patients with achlorhydria and those with normal gastric secretions.[8] In this series 2 of the 3 patients with mild hypochromic anemia had recurrence of anemia although maintained on adequate doses of hydrochloric acid.

Since Einhorn described gastrogenous diarrhea, achlorhydria has been accorded a prominent role in the etiology of functional diarrhea, and excellent therapeutic results with hydrochloric acid have been reported.[2] Achlorhydric diarrhea has been ascribed to rapid gastric emptying or to the loss of bactericidal powers of the gastric juice favoring entry into the intestine of abnormal bacterial flora. Actually, there is little relation between gastric motility and diarrhea, since in uncomplicated duodenal ulcer rapid emptying times are common and yet concomitant diarrhea is rare. Furthermore, constipation is considerably more frequent in achlorhydria than diarrhea. That achlorhydric diarrhea is rare is indicated by the fact that 13 patients in this series had the only cases of anacidity in 282 cases of chronic diarrhea from nonorganic causes studied at my office, a rate of 4.6 per cent. Furthermore, only 1 of these obtained long-term benefit from acid therapy.

It appears that the symptoms associated with achlorhydria are nonspecific and apart from the low frequency of heartburn do not differ from functional complaints of patients with hyperacidity, hypoacidity or normal gastric secretions. Ricketts, Palmer and Kirsner[9] found that the gastrointestinal symptoms of patients without x-ray or gastroscopic evidence of disease were no different from those with atrophic, hypertrophic or chronic superficial gastritis.

Thus, in persons with achlorhydria observed over a long period, the absence of symptoms in many, the lack of symptomatic response to acid therapy in others, the occasional exacerbation of symptoms by such therapy, the recurrence of symptoms during treatment and the spontaneous remissions in those who cannot or do not continue hydrochloric acid indicate that the absence of acid, per se, is not the cause of the diverse symptoms. Since the modern surgical treatment of duodenal ulcer aims at the establishment of anacidity or at least hypochlorhydria it would hardly appear logical to recommend this treatment if it entailed exchanging the ulcer syndrome for the numerous subjective disorders purported to attend deficient acid secretion.

Owing to its association with pernicious anemia, carcinoma of the stomach and gastric polyposis, the presence of achlorhydria in a patient with gastrointestinal complaints always merits careful and repeated evaluation.

Although the symptoms associated with achlorhydria may reflect the associated gastritis, in the large majority of cases in this series the onset and exacerbation of symptoms appeared to be related more directly to the same factors that cause functional dyspepsia in normal persons. Hence, treatment with bland diet, sedation and adequate attention to colonic evacuation appears to be more efficacious than substitution therapy.

148–25 89th Avenue

## References


1. Bockus, H. L. *Gastroenterology*. Vol. 1. 831 pp. Philadelphia: Saunders, 1943. P. 303.
2. Ryle, J. A. Chronic diarrhea. *Lancet* **2**:102-105, 1924.
3. Wilkinson, S. A. Gastric acidity in thyroid dysfunction. *J.A.M.A.* **101**:2097-2099, 1933.
4. Hartung, S. F., and Steinbrocker, O. Gastric acidity in chronic arthritis. *Ann. Int. Med.* **9**:252-257, 1935.
5. Rawls, W. B., and Ancona, V. C. Chronic urticaria associated with hypochlorhydria or achlorhydria. *Rev. Gastroenterol.* **18**:267-271, 1951.
6. Rafsky, H. A., and Weingarten, M. Study of gastric secretory response in aged. *Gastroenterology* **8**:348-352, 1947.
7. Winkelstein, A. Diagnosis, incidence and significance of essential achlorhydria. *Am. J. M. Sc.* **203**:419-428, 1942.
8. Brummer, P. Significance of achlorhydria for etiology of iron-deficiency anemia. *Acta med. Scandinav.* **137**:43-47, 1950.
9. Ricketts, W. E., Palmer, W. L., and Kirsner, J. B. "Chronic gastritis": study of relation between mucosal changes and symptoms. *Gastroenterology* **12**:391-393, 1949.

## SPECIAL ARTICLE

# RADIOACTIVE ISOTOPES IN A COMMUNITY HOSPITAL*

JOHN W. TURNER, M.D.†

SPRINGFIELD, MASSACHUSETTS

THIS year is the twentieth anniversary of the first elaboration of labeled or tagged radioactive isotopes. In May, 1938, Hertz and his associates[1] presented a summary of studies in which radioactive iodine was used as an indicator of thyroid function, soon followed by a paper[2] on the application of radioactive iodine in the therapy of Graves's disease. Thirteen years ago Dr. John Lawrence[3] gave the Caldwell Lecture of the American Roentgen Ray Society, in which he recited numerous biologic and medical applications of various radioactive isotopes already accomplished. Many other physicians and medical nuclear physicists were exploring new possibilities of the use of isotopes in diagnosis and therapy before 1942. These facts should serve as a reminder that atomic medicine was well launched before the era of the atomic bomb. The increased availability of isotopes for medical application since 1946 has tended to make many such projects more practical. The Oak Ridge uranium-pile production of the isotopes has provided quantities not practical during the time of cyclotron use for their production.

The intensified clinical application of isotopes since 1946 has led to the accumulation of a vast and varied experience throughout the United States, as noted in the medical literature and in various other medical contacts. In certain respects clinical application of these substances seems to be currently on firmer ground than some of the newer developments in other fields of medicine.

It is appropriate that the application of radioactive isotopes should keep pace with other medical developments of the past two decades. In more and more small general hospitals throughout the United States medical specialists are available to cope with even the more formidable diagnostic and therapeutic problems. This is a natural consequence of the improved system of specialty training of the past three decades and the rigid specialty-board requirements, as well as improved anesthesia, fluid balance, transfusions and so forth. In many such hospitals angiography, admission photoroentgen-ray survey films of the chest, cardiovascular and adrenal surgery, diagnostic presacral air injection and remarkable extension of radical surgical procedures have become commonplace and successful. It seems incongruous that the well trained young specialist who leaves a large medical center to practice such procedures in a community hospital should not also have in his armamentarium whatever help can be gained from the diagnostic and therapeutic application of radioactive isotopes.

*Presented at the New England Postgraduate Assembly, Boston, October 25, 1954.

†Chief, Department of Radiology, Westfield State Sanatorium; chief, Radiology Service, and Chairman, Isotope Committee, Wesson Memorial Hospital.

### GENERAL CONSIDERATIONS

Those who work in community hospitals might properly look to the university centers in this country and abroad and to federally subsidized projects in their search for isotopes that have been thoroughly tried and found practical for human needs. Fortunately, extensive experimental and research facilities — notably the Oak Ridge Institute of Nuclear Studies — are available in this country. There is no reason to consider the use of radioactive isotopes to be experimental or to conduct any experimental application on patients in small general hospitals; any such information is available from the specially equipped centers. Thus, the practical application at the community-hospital level involves two principal considerations: the use of a particular isotope should improve the accuracy of diagnosis or the effectiveness of therapy in the condition to be dealt with as compared to older or more readily available modalities; and the cost to the patient should be less than, or equivalent to, existing fees for drugs, hospital services and professional fees to accomplish the same medical result.

To some extent these criteria may prove to be mutually compensatory.

The decision concerning the feasibility of a program and the selection of a particular isotope to be employed involves teamwork. One of the many wise provisions of the Atomic Energy Commission regarding medical application of isotopes specifies that these decisions at local-hospital levels shall be made jointly by such specialists as internists, hematologists, pathologists, surgeons, radiologists and medical nuclear physicists. The last are available from large medical centers and university posts on consultation or part-time basis and are important additions to the medical scene.

It is not within the scope of this discussion to explore the details and arguments for, or against, the employment of the numerous isotopes approved for human application. Some of these agents and their uses may be itemized as follows:

### SOME PRACTICAL ISOTOPES

Radioactive iodine ($I^{131}$) for the diagnosis and

therapy of certain thyroid disorders and for some euthyroid cardiac patients.

Radioactive phosphorus ($P^{32}$) for therapy of primary polycythemia rubra vera if the patient volume makes this practical and for chronic leukemias if deep x-ray therapy is not chosen.

Radioactive colloidal gold ($Au^{198}$) or colloidal chromic phosphate ($P^{32}$) for the palliative therapy of cancer in body cavities and for certain selected prostatic and uterine neoplastic lesions.

Radioactive iron,[59] chromium[51] and iodinated human serum albumin ($I^{131}$) may be employed for evaluation of red-cell mass, plasma volume, cardiac output, circulation time and other diagnostic studies (such as those to detect lesions of the brain and liver).

As substitutes for radium, radon and x-ray sources, radioactive strontium ($Sr^{90}$) instead of surface beta radium sources; cobalt ($Co^{60}$) instead of interstitial radium needles, intracavitary radium or surface gamma radium sources or as multicurie telecobalt sources as an alternative for supervoltage x-ray or teleradium therapy; and radioactive gold ($Au^{198}$) instead of permanent radon implants.

Of the foregoing by far the broadest application is that of $I^{131}$, which meets the practical criteria already suggested of effectiveness and cost. The specificity of metabolic localization of $I^{131}$ in the thyroid gland is so remarkable that it seems safe to predict that it will have a permanent and expanding place in medicine. Selection of other isotopes logically varies with hospital needs, individual talents of staff members, background of training in isotope usage and patterns of practice in terms of total patients.

For more than fifty years there have been few restrictions on the use and application of radium and radon by any physician who may choose to employ them. In sharp contrast, in its isotope-distribution policy, the Atomic Energy Commission has imposed reasonable and wise regulations. It is necessary for a local hospital's isotope committee to provide numerous details of personnel, instrumentation, protection and particularly the exact proposed plans of diagnostic and therapeutic dosages for each isotope to be employed. The Commission's authorization is required before procurement of radioactive isotopes is permitted from the original Oak Ridge facilities or the more recently available commercial sources such as Abbott Laboratories or Tracerlab, Incorporated.* Direct instruction and field inspection by personnel of the Commission has done much to protect patients, hospital personnel and physicians from unnecessary hazards.

## An $I^{131}$ Program in a Community Hospital

The remainder of this discussion concerns principally $I^{131}$, but in large measure the considerations involved apply to other isotopes as well. At present the availability of calibrated amounts of $I^{131}$ packaged for individual use and transmitted by air express is quite practical for the small general hospital. It is thus possible to avoid the initial expense, space allotment, labor and maintenance cost in operation of a "hot lab." Decay curves and initial strength are supplied with each shipment. The eight-day half life of $I^{131}$ makes air express practical ($2.87 per shipment) and rail express impractical.

On the basis of precalibrated diagnostic and therapeutic doses from a commercial supplier, it is possible to set up necessary measuring and protective equipment with flexibility for future expansion at a cost of about $1,500 to $1,800. Less than this amount can be spent, or, of course, a great deal more.

Table 1. *Examples of Radiation Levels.*

| Level | Amount |
|---|---|
| Safe radiation level per week | 300 milliroentgens (International Standard) |
| Safe tracer dose of $I^{131}$ | 2.28 microcuries/kg. or 300 milliroentgens/wk. |
| Usual diagnostic dose of $I^{131}$ | 5-40 microcuries |
| Example of therapeutic dose (20 microcuries x 200) | 4 millicuries |
| Level of radiation requiring hospital supervision | 30 millicuries |
| Radiation from cosmic rays & natural radioactivity to human race since time began | 750 mr./yr. |

The initiation of a program carries with it a real necessity for attention to purely radiation hazards. This involves proper care in the storage and supervision of use and disposal of all materials according to well established physical facts and policies. Of almost equal necessity is the problem of reassurance regarding absence of radiation hazards. Many patients and hospital personnel are not aware of the accuracy and knowledge of physical measurement of radiation available to all. Physicists and instrument makers deserve much credit for taking the guesswork out of what a radiation hazard is and is not, but patients are still "atom conscious" and suspicious. The referring physician is often besieged with questions and presents a reasonable curiosity of his own about the plans for isotope usage. The late Dr. William T. Salter, a very capable thyrologist and pharmacologist, of Boston and later of New Haven, was amused by the paradox that hospital personnel seem fearful and suspicious of diagnostic test doses of $I^{131}$ even though many of these people wear luminous watch dials of similar measurable radioactivity. The amount of radiation involved in the usual $I^{131}$ diagnostic test is much less than that incurred in a lumbosacral x-ray examination. Various levels of radiation[4] are shown in Table 1.

Concern has been expressed about the carcinogenic effect of $I^{131}$ especially from the larger doses as for therapy. After fifteen years, no clear-cut cause-and-

*Tracerlab, Incorporated, discontinued this service from Philadelphia on November 5, 1954, leaving Abbott Laboratories as the principal supplier.

effect relation has been observed. Ionizing radiation began falling on nonmalignant thyroid tissue in large amounts much longer than fifteen years ago in the x-ray and radium therapy of hyperthyroidism, and treatment of cancers of neighboring tissues such as the larynx and cervical lymph nodes where the thyroid gland was included, without the observation of any remarkable tendency for carcinogenic effect of ionizing radiation on normal thyroid tissue.

Permanent radon implants in benign lesions such as hemangiomas resemble in some particulars the metabolic localization of $I^{131}$ in the thyroid gland. Both $I^{131}$ and radon have beta and gamma emission; both have short half lives (8 and 3.85 days respectively), and even though radon is all retained in such sealed sources during its decay, carcinogenesis from permanent radon implants in hemangiomas is not encountered.

Hazards that are of some consequence deserve attention. As a general rule the administration of $I^{131}$ to pregnant or lactating patients is avoided. The fetal thyroid gland has been shown by Chapman and his associates[5] to pick up $I^{131}$ after the fourteenth week. The iodine content of human milk makes the possible level of $I^{131}$ secretion by this medium sufficient to justify avoidance of unnecessary radiation of the nursing infant's thyroid gland.

There seems to be no valid physical or biologic evidence to support earlier theories that ovarian or testicular injury might result from the excreted $I^{131}$ in urine or levels of $I^{131}$ in pelvic tissue. The maximum 2.2-mm. pathway of the ionizing beta radiation of $I^{131}$ and the average penetration of less than 1 mm. is not sufficient to injure these structures for much the same reason that it does not injure the human parathyroid glands. The beta radiation is spent before it reaches from peripheral thyroid cells to the parathyroid glands. It is to be remembered that the gamma radiation from $I^{131}$ is a minimal but proportionate amount and has practical application in physical measurement, as for external counting, but no significant tissue effect. Müller and Brunner[6] describe a patient who completed a normal pregnancy after large doses of $I^{131}$ for control of metastases from thyroid cancer. The total dosage of 95 millicuries is about ten or twenty times the amount required for the therapy of Graves's disease.

### Diagnosis

Most of the diagnostic uses of $I^{131}$ in hyperthyroidism, obesity, post-thyroidectomy problems, euthyroid cardiac disease, hypothyroidism, follow-up study of thyroiditis, counting of wet specimens and autoradiography — are self-explanatory. An estimate of the degree of hyperthyroidism is often helpful. My experience coincides with the generally accepted observation that there is comparatively less elevation of uptake in toxic nodular goiter than in diffuse toxic goiter. It is often helpful to know the thyroid function in attempted correction and management of obesity. Symptoms of hyperthyroidism after thyroid surgery can often be evaluated accurately by uptake studies. In euthyroid cardiac disease it is desirable to determine that thyroid function is truly within normal range, particularly if $I^{131}$ therapy is planned. Hypothyroidism is evaluated with ease and accuracy by uptake determination. In my limited experience patients who have had thyroiditis have low uptake levels. I have gained information in co-operation with the surgeon and the pathologist by measuring wet specimens in different ways: the total specimen; right lobe versus left lobe; gross disease versus grossly normal tissue; and the wet specimen compared to the patient's neck immediately after the operative procedure. Autoradiography, for correlation with histologic information, is an easily accomplished and wise routine procedure for solitary thyroid nodules and suspected thyroid cancer.

### Treatment

Therapeutic applications of $I^{131}$ are as follows: in hyperthyroidism persistent or recurrent after earlier surgical intervention on one or more occasions; in patients who refuse surgery or who are considered poor surgical risks; in destruction of residual normal thyroid tissue after attempted total thyroidectomy (to improve uptake in well differentiated metastatic foci from thyroid cancer); and in euthyroid cardiac patients who might be benefited by reduction of metabolic activity — for example, those with intractable angina and recurrent pulmonary edema.

It is encouraging to note that good results are being obtained quite generally from $I^{131}$ therapy in such cases. Seed,[7] an experienced thyroid surgeon, has ventured the prophecy that "unless there appears very soon a clinical example wherein radioactive iodine has induced cancer of the thyroid, the present surgical treatment of exophthalmic goiter will be replaced largely by radio-iodine therapy."

Treatment of thyroid cancer by $I^{131}$ has a limited application because only about 15 to 20 per cent of metastases are adequately differentiated to capture significant amounts of radioactive iodine. Surgery and deep x-ray therapy remain the important measures for these problems.

The prevalence of cardiovascular disease and the prospect of reducing metabolic demands without the risk of thyroidectomy[8,9] have revived interest in this form of therapy in selected patients.

At the community-hospital level these concepts are borne in mind — again with the attitude of applying what has already been subjected to successful clinical application in large centers rather than in any spirit of local experimentation.

## Conclusions

Several developments of recent years favor the initiation and operation of isotope programs for even

the smaller general hospitals: the distribution program of the Atomic Energy Commission initiated in 1946; the availability of precalibrated diagnostic and therapeutic units delivered by air-transport facilities from commercial sources; the availability of isotope training for physicians and of part-time consultant medical nuclear physicists; the availability of reasonably priced radiation detection and measurement equipment; and, most important of all, the accumulation of well documented clinical experience especially in $I^{131}$ usage.

After twenty years of research in physical aspects, animal experimentation and, in the past fifteen years, increasing application of radioactive isotopes for human needs, there are many cases in which an isotope like $I^{131}$ is of practical value, meeting criteria of effectiveness and cost for use in the community hospital. Teamwork among interested physicians and logical awareness of effects of isotopes without blind or illogical fear of them should guide the development and operation of an isotope program. $I^{131}$ has a permanent and expanding place in the diagnosis and therapy of selected thyroid problems and in certain euthyroid cardiac patients who are likely to benefit by lessened metabolism.

In the western New England area, John C. Larkin, M.D., of New Britain, Connecticut, deserves credit for pioneer work in this field and for bringing to bear on such clinical problems a thorough knowledge of medical physics as well as of clinical medicine.

### References

1. Hertz, S., Roberts, A., and Evans, R. D. Radioactive iodine as indicator in study of thyroid physiology. *Proc. Soc. Exper. Biol. & Med.* 38:510-513, 1938.
2. Hertz, S., and Roberts, A. Application of radioactive iodine in therapy of Graves' disease. *J. Clin. Investigation* 21:624, 1942.
3. Lawrence, J. H. New nuclear physics and medicine. *Am. J. Roentgenol.* 48:283-301, 1942.
4. Chantraine, H. Erbschädigung durch Röntgenstrahlen? *Röntgen-Blätter* 5:1-10, 1952.
5. Chapman, E. M., Corner, G. W., Jr., Robinson, D., and Evans, R. D. Collection of radioactive iodine by human fetal thyroid. *J. Clin. Endocrinol.* 8:717-720, 1948.
6. Müller, J. H., and Brunner, C. Normaler Partus eines gesunden Mädchens nach erfolgreicher Behandlung einer metastasierenden Struma maligna der Mutter mittels radioaktiven Jods ($I^{131}$). *Schweiz. med. Wchnschr.* 83:54, 1953.
7. Seed, L., and Fields, T. *Treatment of Toxic Goiter with Radioactive Iodine.* 128 pp. Springfield, Illinois: Thomas, 1953.
8. Blumgart, H. L., Freedberg, A. S., and Kurland, G. S. Treatment of incapacitated euthyroid cardiac patients by producing hypothyroidism with radioactive iodine. *New Eng. J. Med.* 245:83-91, 1951.
9. Jaffe, H. L., Rosenfeld, M. H., and Pobirs, F. W. Radioiodine in treatment of advanced heart disease: end results in 100 patients. *J.A.M.A.* 151:716-720, 1953.

# MEDICAL PROGRESS

## ENDOSCOPY (Concluded)*

Edward B. Benedict, M.D.†

BOSTON

### Gastroscopy

#### Technic

In an article on the difficulties in the differential diagnosis of gastric carcinoma and gastritis, Kennedy[139] states that it is reasonable to assume that in the future no gastroscopic examination will be complete unless biopsy under direct vision is available.

Selesnick and Kinsella[140] made a study of gastritis and gastroscopic biopsy whose purpose was to examine the validity of Benedict's belief that no gastroscopic examination is complete unless biopsy under direct vision is available. A review of 56 satisfactory gastroscopic examinations, including biopsy of gastric mucosa under direct vision, in 50 patients considered to have either grossly normal mucosa or gastritis appeared to validate Benedict's belief that gastroscopy is not complete without mucosal biopsy under direct vision. This seems to be especially true in cases of normal-appearing mucosa and patients considered to manifest chronic hypertrophic gastritis. It is proposed that physiologic alterations — possibly areae gastricae — may simulate chronic hypertrophic gastritis.

*From the Surgical Services, Massachusetts General Hospital, and the Department of Surgery, Harvard Medical School.

†Assistant clinical professor of surgery, Harvard Medical School; endoscopist, Massachusetts General Hospital.

Atwater[141] has discussed the use of anesthetic agents in gastroscopy. He believes that by utilizing the excellent relaxation of the abdominal musculature, the gastroscopist can, with abdominal palpation, bring into view the prepyloric area, especially along the lesser curvature, as well as other difficult areas in a far greater number of cases if the intravenous-anesthetic approach is used. Although the taking of a biopsy with the Benedict operating gastroscope is not necessarily difficult, anyone who has undertaken this procedure realizes that at times biopsy can become tedious and trying. When local anesthetics are used, attempts to obtain adequate biopsies may prolong the examination and bring about considerable inconvenience and unpleasantness to the patient. With intravenous anesthesia multiple gastric biopsies may be taken without an added risk or discomfort to the subject.

Johnston[142] has described a new rotating gastroscopic table. Rotation can be arrested, restarted or reversed at will by means of an electric switch control. With this gastroscopic rototable, as it has been called, fixed upon the conventional operating table, the head or foot may be raised or lowered to take further advantage of gravitational forces in the vertical plane.

It is the author's opinion that this rotating table greatly increases the visibility and minimizes the blind areas. It is found to be a perfectly safe procedure.

Paulson[143] calls attention to the fact that the flexible biopsy gastroscope (Benedict operating gastroscope) may be used as a jejunoscope or duodenoscope, thereby revealing a small segment of the small intestine or duodenum contiguous to an anastomosis. The commonest disturbance noticed with the endoscope is jejunitis after esophagojejunostomy. A single recurring neoplasm involving the jejunum was discerned by this method. Material for biopsy and cell-block examination can be obtained by means of the flexible biopsy gastroscope.

Doig and Wood[144] are continuing to use a flexible biopsy tube that is introduced blindly into the stomach. By this method it has been possible to establish the presence of superficial or atrophic gastritis and to investigate its etiology, symptomatology, course and prognosis — this may be important since the disease is frequently mistaken for cancer of the stomach. Also, the changes in the gastric mucosa associated with pernicious anemia and subacute combined degeneration of the spinal cord can be studied, and the effects of treatment observed; serial biopsies have led the authors to the belief that liver therapy causes no regeneration of the gastric mucosa even after many years of treatment. The relation between the secretions of the gastric mucosa and its morphology can be investigated. It has been found that there is a direct correlation between atrophy and the volume, concentration of free acid and pepsin content of gastric secretion after histamine stimulation. Finally the effects on the gastric mucosa of damaging agents such as alcohol and deep x-ray therapy can be studied (x-rays have been used in the treatment of duodenal ulcer since the work of Ricketts and others — reported in 1948 — in America).

Doig and Wood[145] have also reviewed a series of 112 cases of diffuse gastritis (48 cases of superficial and 64 cases of atrophic gastritis) and compared the etiology, symptomatology, diagnosis, prognosis and management with those in a similar series of cases of gastric and duodenal ulcer. The diagnosis was made from the history, physical and test-meal examinations and the histologic appearance of fragments obtained by the flexible gastric-biopsy tube designed by them. No constant etiologic factor was found. The most important factor was chronic alcoholism with malnutrition.

Funder and Weiden[146] carried out gastric biopsy and examination with the histamine test meal on a series of 268 patients. The lesions of superficial and atrophic gastritis were associated with a depression of hydrochloric acid secretion, more severe with atrophic gastritis than with superficial gastritis. All patients with gastric atrophy (those with pernicious anemia or subacute combined degeneration of the spinal cord or both) had achlorhydria.

Rubin, Goldgraber and Smith[147] have described an improved gastric-biopsy tube. Both antral and fundal segments of the stomach may be sampled with this instrument. The 2 hemorrhagic complications that occurred in over 200 biopsies are described, and a routine is outlined to minimize this risk. The limitations and possible fields of usefulness of this new tool are discussed. These authors also refer to reports from other clinics that 3 patients required transfusions after a successful biopsy. In their own series an outpatient with pernicious anemia became nauseated and faint within two hours of examination but did not call until he had vomited 900 cc. of blood eight hours later. Nevertheless, immediate hospitalization and transfusion resulted in uneventful recovery.

Goldgraber et al.[148] studied 3 patients undergoing x-ray therapy for duodenal ulcer by means of a modified Wood biopsy tube. Forty biopsies were taken in each patient over a four-month period. Although the histologic changes varied in severity among the 3 patients, they were similar in pattern. The patchy nature of these changes was stressed. The earliest change observed was coagulation necrosis of the depths of the fundal glands involving both chief and parietal cells. As this process progressed upward the pits deepened, and the neck cells proliferated. The necrotic tubules sloughed and were replaced in part by neck cells and partly by round-cell infiltration. At the peak of the reaction there was partial to complete loss of glandular substance with mucosal thinning, edematous interstitial tissue with predominantly chronic inflammatory infiltration and striking changes in the superficial epithelium. Reversion to normal was prompt and complete. Certain aspects of the radiation reaction are similar to the gastric changes observed after many other types of trauma. This type of study makes it possible to follow histologically the mucosal response to trauma.

Benedict[149] has again emphasized the great value of gastroscopic biopsy in the differential diagnosis of carcinoma, lymphoma and gastritis. Four hundred gastroscopic biopsies have been obtained by means of the Benedict flexible operating gastroscope. There have been no complications. The value of an exact pathological diagnosis is obvious. No gastroscopic examination is complete without biopsy. A new field has been developed for the pathological study of gastric tissue.

#### Evaluation

Klotz, Kirsner and Palmer[150] analyzed 1382 satisfactory gastroscopic examinations in 970 patients. Indecisive x-ray diagnosis in all cases in this series was reduced from 30 to 11 per cent by the additional examination of gastroscopy. Only 1 lesion is known to have been overlooked in the 1382 successful gastroscopic examinations and the corresponding radiologic studies. Seventy-two, or 88 per cent, of 82 surgically proved neoplasms were correctly diagnosed by x-ray

study, and 66, or 80 per cent, by gastroscopy. All the lesions were seen by x-ray examination or gastroscopy or both, and the combined procedures reduced the error in diagnosis in this series to 6 per cent; it is apparent that if fewer errors in the diagnosis of gastric cancer are to be made both are necessary. In 33 cases of large folds the rate of indecisive diagnoses by radiology alone was 51.5 per cent. Eighty-two per cent of these cases were correctly and 18 per cent incorrectly diagnosed by gastroscopy; the error by the combined procedures was 12 per cent. The diagnosis of benign gastric ulcer on the basis of clinical findings, x-ray examination and gastroscopy was correct in 95 of 96 cases in which the lesion was visualized gastroscopically.

Selesnick and White[151] studied the implications of failure of the gastroscope to pass the cardiac orifice of the stomach. In their experience the gastroscope failed to pass the cardiac orifice in 2.9 per cent out of 900 consecutive gastroscopic examinations. The records of 26 patients in whom the instrument could not be passed were analyzed in detail, as follows: neoplasms of the stomach, 9; pancreatitis, 4; enlargement of the liver, 1; subphrenic abscess or adhesions, 2; emphysema, 5; paraesophageal hernia, 1; cardiac hypertrophy, 1; and esophagitis, 1. Repeated failure to pass the instrument into the stomach should be viewed as strong evidence of an abnormality that should be clarified by other diagnostic methods.

In a study of the diagnostic accuracy of gastroscopy in neoplasms of the stomach Baker, Gorvett and Spellberg[152] conclude that by x-ray examination, accuracy of diagnosis was 68 per cent whereas by gastroscopic examination, it was 73 per cent — a difference not statistically significant. The combined methods raised the rate of accuracy to 91.5 per cent. Gastroscopic error is due mostly to inadequate visualization of the lesion. When the lesion can be brought into view this method proves more accurate than x-ray examination. Gastroscopy is an adjuvant to, and not a substitute for, roentgenology in the diagnosis of gastric neoplasms.

#### Gastritis

Sarason and Levy[153] report a case of acute gastric erosions associated with massive hematemesis occurring in the wake of a cerebrovascular accident for which a successful gastrectomy was performed. Autopsy at a later date showed that the cerebral lesion involved the internal capsule and areas of the brain supplied by the middle cerebral arteries. No pathologic changes in the hypothalamus were noted. The pathogenesis of acute gastric ulceration occurring under such circumstances is discussed from the point of view of the "neurogenic-ulcer" thesis of Cushing as well as the "stress-ulcer" hypothesis of Selye. The clinical management of acute superficial gastric erosions may pose a serious surgical problem by virtue of massive hematemesis incident to erosion of sclerotic submucosal vessels, as in the case presented.

Rider, Klotz and Kirsner[154] describe a case of gastritis with venocapillary ectasia as a source of massive gastric hemorrhage. In a patient with massive gastrointestinal bleeding the hemorrhage arose in an unusual type of gastritis characterized by venocapillary ectasia. The lesion was demonstrated at gastroscopy after all other clinical procedures, including abdominal exploration, had failed. Histologic examination of the resected stomach revealed gastritis with greatly dilated, thin-walled vessels at the most superficial levels of the mucosa.

#### Gastric Ulcer

Silk, Blomquist and Schindler[155] studied 18 ulcers of the greater curvature, of which 10 proved to be malignant (7 carcinomas and 1 lymphoblastoma), and 8 benign, a ratio of 5:4. In a recent autopsy report an even higher proportion of benign ulcers was found, in an approximate ratio of 1:1. Therefore, the location of an ulcer on the greater curvature should no longer be taken as definite evidence of neoplasm. In addition to other clinical methods gastroscopic examination is an important adjunct in the differential diagnosis of benign and malignant ulcers of the greater curvature, since the greater curvature is readily accessible to gastroscopic observation.

Schindler and Desneux,[156] in a study of 273 gastric ulcers, state that the percentage of correct gastroscopic diagnoses is so high and the diagnosis is possible in many cases with such certainty that gastroscopy must be considered an extremely valuable method for the correct differential diagnosis of gastric ulcer; perhaps it is even the most valuable method.

Whitehouse and Kent[157] report a case of persimmon bezoar with gastric ulcer, which until gastroscopic examination had been in doubt:

> Gastroscopic examination was done. . . . There was an elliptically shaped, dark green, irregular mass, measuring about 7 x 4 x 4 cm., lying free in the dependent portion of the stomach. In the pyloric antrum, with the button at 10 o'clock there was a clean cut gastric ulcer with a grayish base and an edematous rim of normal orange-red mucosa . . . The gastroscopic diagnosis was persimmon bezoar and benign gastric ulcer.

These findings were confirmed at operation.

#### Carcinoma

Marshall[158] has presented a case in which giant, but otherwise normal, gastric folds simulated carcinoma of the stomach. It is necessary to differentiate such cases from those in which there is marked inflammation. Gastroscopy with visual observation combined with biopsy provides a mean by which this distinction may be made.

#### Other Malignant Gastric Tumors

In a series of 79 cases of resected isolated malignant lymphoma of the gastrointestinal tract reported by Allen and his associates,[159] 44 involved the stomach,

25 the small bowel, 9 the large bowel, and 1 the esophagus. A radical operation similar to that for cancer was performed in each case, usually followed by irradiation therapy. The over-all five-year survival rate was 43 per cent, excluding 16 operative deaths. I should like to point out that it is now possible in many cases to establish a positive diagnosis of gastric lymphoma by means of a positive biopsy of a specimen obtained with the Benedict flexible operating gastroscope.

Engberg[160] states that primary lymphosarcoma makes up at least 0.5 to 1 per cent of all gastric neoplasms. Hitherto, nearly 600 cases have been reported. The symptomatology is reviewed, and certain features that may make possible the differential diagnosis of carcinoma and lymphosarcoma are emphasized. The differential diagnosis is of great importance in view of further procedures. The treatment is always total gastrectomy, which is often possible even in cases with massive tumors. Postoperative x-ray therapy is recommended; the tumor is highly radiosensitive. The prognosis has proved to be surprisingly better than that of carcinoma, and the five-year survival rate is high and still increasing. Even advanced cases of so-called inoperable carcinoma call for exploratory laparotomy to rule out lymphosarcoma. Two cases studied personally by Engberg are reported. It should be emphasized that gastric biopsy may in some cases eliminate the necessity for exploratory laparotomy.

#### Miscellaneous Conditions Affecting the Stomach

Goodale and Sniffen[161] have reported the case of a fifty-eight-year-old man in whom a tumor of the stomach was noted on routine x-ray work-up. Gastroscopic examination showed hypertrophied gastric rugae without ulceration, and a biopsy was reported as acute gastritis. A total gastric resection was followed by uneventful recovery. The stomach was larger than normal, with dilated veins along the lesser curvature. The rugal folds throughout the cardia, fundus and body of the stomach were greatly hypertrophied, pale, pink and glistening. This lesion is not considered malignant or premalignant. The practical importance of mucosal hypertrophy of the stomach is in its differentiation from hypertrophic gastritis, malignant tumor and diffuse polyposis. Even gastroscopic examination reveals only large rugae without ulceration, and biopsy is encouraging only in a negative way. However, neither rules out infiltrating carcinoma.

A similar case was recently discussed in the Case Records of the Massachusetts General Hospital.[162] The diagnosis was not correctly made either by the operating surgeon or by the physician reviewing the clinical findings.

In an article on familial polyposis Halsted, Harris and Bartlett[163] studied 7 members of a family with this disease of whom 5 had diffuse involvement of the stomach in addition to the colon. The significant feature of the study was that gastroscopic examination identified the polyposis whereas x-ray examination had failed to reveal it in 4 of the 5 cases because the polyps were so small. These findings indicate that gastroscopy ought to be performed in every patient with diffuse familial polyposis of the colon, since this is the most accurate method by which diffuse gastric polyposis may be diagnosed.

Leodolter[164] has described a parapancreas of the lesser curvature of the stomach that had been diagnosed as ulcer by x-ray and as benign tumor by gastroscopic examination. The x-ray, gastroscopic and histologic findings are shown in figures.

#### Peritoneoscopy

Peritoneoscopy has been used routinely by Fourès, Ricordeau and Caroli[165] for more than four years in patients with hepatobiliary conditions in whom a diagnosis could not be established by clinical, biologic or radiologic methods of investigation. Peritoneoscopic examination can be supplemented by puncture biopsy of the liver, angiocholegraphy and radiomanometry of the biliary passages, all of which can be performed with greater accuracy and safety under the visual control provided by the peritoneoscope. The information that can be obtained from these supplemental procedures when they are carried out according to the technic and with the precautions described by the authors may suffice to establish a diagnosis in difficult cases in which other diagnostic methods have failed.

Hegstrom, Zoeckler and Keil[166] have reviewed 800 peritoneoscopic examinations. Eight hundred and seventy-one liver biopsies were obtained, and 57 direct cholangiograms performed. One death occurred early in the series. This procedure has greatly facilitated diagnosis of intra-abdominal disease, particularly of the biliary system. Liver biopsy was obtained almost routinely. The inadequacy of the punch biopsy and the frequency of moderate hemorrhage prompted the authors to discontinue this technic in favor of the forceps technic. The larger biopsy obtained by the forceps permits evaluation on a lobular basis, and has been found to be much more satisfactory. They have encountered significant hemorrhage from the forceps biopsy site on only one occasion.

Keil et al.[167] state that biopsies obtained with the forceps technic (peritoneoscopy) were much superior to needle biopsies, in which the sections often contained such small portions of lobules that they were frequently inadequate for an accurate histologic diagnosis. In some cases the tissue was considerably traumatized by the needle, further reducing the value of a biopsy already of questionable worth because of its minute size. There is a close correlation between the gross and the microscopical picture of hepatic disease (74 per cent of this series). Biopsy of the liver

by the forceps method is more satisfactory for routine purposes than the Silverman punch technic. The changes readily elicited by biopsy of the liver are as follows: fatty metamorphosis, bile stasis, cirrhosis, metastatic neoplasm and malignant lymphoma, nonspecific granuloma and cholangitis. Recognizable but less easily interpreted are toxic hepatocellular damage, scattered inflammatory cells in liver sinusoids, fibrotic changes near the liver capsule and foci of necrosis. The considerable difference of opinion in the literature about whether the histologic picture correlates with liver-function tests may be explained by the fact that needle biopsies are often inadequate for histologic diagnosis.

Pearce[168] has described needle biopsy of the liver under peritoneoscopic visualization. The value of liver biopsy has been demonstrated in numerous recent papers. Most observers with experience have noted the complications of blind needle biopsy. These are hemorrhage, bile peritonitis, puncture of a hollow viscus, pulmonary infection, pneumothorax, pain, implantation of tumor cells in the needle technic and air embolism. The danger of hemorrhage may be minimized by routine fulguration of the site of the needle puncture of the liver. The advantages of peritoneoscopy of the abdominal cavity and liver, together with direct vision of a transabdominally placed needle for liver biopsy under direct vision, are emphasized. The dangers of blind needle biopsy can be minimized or prevented by this method.

MacFadyen, Reishtein and Kannapel[169] have employed endoscopy in gynecology in an effort to establish the correct diagnosis in 191 patients whose symptoms and pelvic findings did not unequivocally warrant abdominal surgery. Of 167 patients (87 per cent) in whom the diagnosis was established by this method, the culdoscope was used in 141, and the peritoneoscope in 26. In the remaining 24 (13 per cent) failure to enter the peritoneal cavity or inadequate visualization made positive diagnosis impossible. The method proved particularly valuable in the rapid identification of ectopic pregnancy, chronic bilateral salpingitis, endometriosis, adnexal neoplasm and abnormal pelvic conditions associated with anxiety states. Serious complications were associated with culdoscopy in 11 patients (6.8 per cent). Two rectal perforations occurred early in this series. There was no mortality. No complications followed peritoneoscopy.

Zoeckler, Keil and Hegstrom[170] state that peritoneoscopy is not intended to replace exploratory laparotomy. Like the roentgenologic and laboratory study it is an aid in the complete evaluation of gastrointestinal problems. It is a valuable procedure in the diagnosis and management of the patient with carcinoma. Metastatic lesions were demonstrated in 51.3 per cent of patients who appeared to have localized carcinoma by conventional roentgenologic and laboratory studies. Recurrent or metastatic carcinoma was demonstrated in 50 per cent of patients who had previously undergone resections for operable carcinoma. Ninety-three per cent of patients with a diagnosis of malignant lesions, based on clinical findings that could not be refuted by appropriate laboratory and roentgenologic studies, were shown peritoneoscopically to have diseases other than carcinoma. Peritoneoscopy is a valuable procedure in the diagnosis and prognosis of carcinoma involving intraperitoneal structures.

## References


139. Kennedy, T. J. Difficulties in differential diagnosis of gastric carcinoma and gastritis: surgical considerations. *Radiology* **59**: 367-370, 1952.
140. Selesnick, S., and Kinsella, E. D. Gastritis and gastroscopic biopsy. *New Eng. J. Med.* **248**:842-844, 1953.
141. Atwater, J. S. Use of anesthetic agents in gastroscopy. *Gastroenterology* **23**:60-65, 1953.
142. Johnston, C. C. New rotating gastroscopic table. *Bull. Am. Gastroscopic Soc.* **3**:2, 1954.
143. Paulson, M. Peroral jejunoscopy and duodenoscopy: endoscopy of uppermost small intestine after total gastrectomy. *Gastroenterology* **23**:593-606, 1953.
144. Doig, R. K., and Wood, I. J. Gastric biopsy using flexible gastric biopsy tube. In *Modern Trends in Gastro-Enterology*. Edited by F. A. Jones. 281 pp. London: Butterworth, 1952. Pp. 352-360.
145. *Idem*. Gastritis: study of 112 cases diagnosed by gastric biopsy. *M. J. Australia* **1**:593-600, 1952.
146. Funder, J. F., and Weiden, S. Correlation between test meal findings and histology of stomach as shown by gastric biopsy. *M. J. Australia* **1**:600-602, 1952.
147. Rubin, C. E., Goldgraber, M. B., and Smith, C. Improved gastric biopsy tube: its manufacture, use and investigative value. *Gastroenterology* **25**:31-43, 1953.
148. Goldgraber, M. B., Rubin, C. E., Palmer, W. L., Dobson, R. L., and Maney, B. W. Early gastric response to irradiation: serial biopsy study. *Gastroenterology* **27**:1-20, 1954.
149. Benedict, E. B. Gastroscopy with biopsy: differential diagnosis of carcinoma of stomach. *Missouri Med.* **52**:23-25, 1955.
150. Klotz, A. P., Kirsner, J. B., and Palmer, W. L. Evaluation of gastroscopy. *Gastroenterology* **27**:221-226, 1954.
151. Selesnick, S., and White, B. V. Implications of failure of gastroscope to pass cardiac orifice of stomach. *Gastroenterology* **21**:507-515, 1952.
152. Baker, L., Gorvett, E. A., and Spellberg, M. A. Diagnostic accuracy of gastroscopy in neoplasms of stomach. *Cancer* **5**:1116-1127, 1952.
153. Sarason, T. L., and Levy, B. F. Pathogenesis and surgical management of acute gastric erosions. *New Eng. J. Med.* **251**:769-772, 1954.
154. Rider, J. A., Klotz, A. P., and Kirsner, J. B. Gastritis with veno-capillary ectasia as source of massive gastric hemorrhage. *Gastroenterology* **24**:118-123, 1953.
155. Silk, A. D., Blomquist, O. A., and Schindler, R. Ulcer of greater gastric curvature. *J.A.M.A.* **152**:305-307, 1953.
156. Schindler, R., and Desneux, J. Gastroscopic diagnosis in 273 gastric ulcers. *Gastroenterology* **24**:327-338, 1953.
157. Whitehouse, F. R., and Kent, J. F. Persimmon bezoar with gastric ulcer: gastroscopic observation of case. *Gastroenterology* **25**: 290-295, 1953.
158. Marshall, D. Giant rugae with normal overlying mucosa simulating gastric neoplasm: report of case. *Gastroenterology* **23**:665-672, 1953.
159. Allen, A. W., Donaldson, G., Sniffen, R. C., and Goodale, F., Jr. Primary malignant lymphoma of gastro-intestinal tract. *Ann. Surg.* **140**:428-438, 1954.
160. Engberg, J. Lymfosarcomer i ventriclen. *Nordisk med.* **38**:1610-1613, 1953.
161. Goodale, F., Jr., and Sniffen, R. C. Mucosal hypertrophy of stomach: report of case. *New Eng. J. Med.* **249**:1105-1107, 1953.
162. Case Records of the Massachusetts General Hospital (Case 34451). *New Eng. J. Med.* **251**:823-836, 1954.
163. Halsted, A. A. Familial polyposis. *Gastroenterology* **28**:932, 1954.
164. Leodolter, I. Pancreas aberrans in stomach: report of case. *Gastroenterology* **24**:569-572, 1953.
165. Fourès, A., Ricordeau, P., and Caroli, J. Technique de la péritonéoscopie: biopsie du foie, angiocholégraphie, radiomanométrie sous contrôle péritonéoscopique. *Presse méd.* **62**:929-933, 1954.
166. Hegstrom, G. J., Zoeckler, S. J., and Keil, P. G. Peritoneoscopy. *Gastroenterology* **25**:243-247, 1953.
167. Keil, P. G., Landis, S. J., Cross, K. R., and Corcoran, T. E. Evaluation of liver biopsy. *Ann. Int. Med.* **38**:1278-1294, 1952.
168. Pearce, A. E. Needle biopsy of liver under peritoneoscopic visualization. *Gastroenterology* **27**:46-49, 1954.
169. MacFadyen, B. V., Reishtein, W. A., and Kannapel, A. R. Endoscopy in gynecology. *Am. J. Obst. & Gynec.* **64**:319-325, 1952.
170. Zoeckler, S. J., Keil, P. G., and Hegstrom, G. J. Peritoneoscopy in malignant lesions of abdomen. *J.A.M.A.* **154**:1617, 1953.

## MEDICAL INTELLIGENCE

# RUPTURE OF SPLENIC-ARTERY ANEURYSM

## Report of a Case with Operation and Recovery

GIOACCHINO SISTO PARRELLA, M.D.*

MILFORD, CONNECTICUT

NEXT to those of the aorta, aneurysms of the splenic artery are the most common intra-abdominal aneurysms.[1] In spite of this, the disease is rarely recognized before surgery or autopsy. In a collected series of 144 cases reported by Cosgrove, Watts and Kaump,[2] the preoperative diagnosis was made in only 10. The hope for survival in these cases rests on immediate diagnosis. The surgeon must be alert to the possibility of this condition, particularly in the advanced stages of pregnancy. Tonge[3] mentions only 2 survivals after surgery of ruptured splenic-artery aneurysms in pregnancy, whereas Dobson, Morse and Covert[4] have presented the fifth survival in 20 collected cases of all types with operation after perforation.

### CASE REPORT

B.N., a 38-year-old divorcee, was admitted to Milford Hospital on December 25, 1953, complaining of severe abdominal pain of 3 hours' duration. Three weeks previously she was riding in the right front seat of a car that had come to a sudden stop. To prevent her from striking the windshield, the driver forcefully restricted her forward motion by pressing his right elbow into the left side of her abdomen. An hour after the onset of the pain she began to vomit, and the pain localized in the right side of the abdomen. A mass appeared in the right upper quadrant, which gradually shifted to the left side.

Physical examination revealed a very obvious asymmetry of the abdomen, with a tympanitic, tender mass located to the left of the umbilicus and roughly 9 by 18 cm. in size. The impression of a volvulus, probably of the sigmoid, was confirmed by x-ray study.

At operation a volvulus of the cecum was found that was easily reduced and fixed to the lateral gutter. The postoperative course was quite good for the first 2 days. On December 31 abdominal distention and vomiting became marked. The white-cell count was 22,000, and a plain film showed dilated small-bowel loops and intra-abdominal fluid. Reoperation was performed on the same day through the previous incision. There was some blood-stained fluid in the abdomen and blood clots in the pelvis. The spleen, pancreas and kidneys were normal to palpation. The small bowel was diffusely distended, but no obstruction was found. A small hemangioma, 1.5 cm. in diameter, was seen in the right lobe of the liver. There were 2 small blood clots in the gastrocolic ligament.

The patient again did well postoperatively, but suddenly, on January 5, she sat up in bed with excruciating epigastric pain exaggerated by respiration. Tenderness was elicited in the right upper quadrant and was associated with pain in the tip of the right shoulder. The upper abdomen appeared to be diffusely distended. After a transfusion she immediately improved. The impression at this time was that she had had an abdominal hemorrhage, probably in the lesser bursa. She had begun to eat well and the bowels were moving normally, when suddenly, on January 9, 1954, she went into peripheral vascular collapse with intense pain in the upper abdomen and below the sternum. A mass was felt in the left upper quadrant, increasing rapidly in size over the course of several minutes. A diagnosis of massive hemorrhage in the lesser omental bursa was made. With 3 transfusions running simultaneously, the abdomen was explored through a left subcostal incision. A large hematoma in the lesser bursa was encountered. At the superior border of the pancreas near the origin of the splenic artery, there was an organizing hematoma, with a cavity at its center, from which bright-red blood was spurting. The cavity measured approximately 2.5 cm. in diameter and apparently opened into the splenic artery at its proximal portion. To control the bleeding from the splenic artery it was decided to mobilize the tail of the pancreas. The distal two thirds of the splenic artery was then removed, together with the tail of the pancreas and the spleen. The splenic artery was ligated close to the celiac axis.

Pathological examination revealed organizing peripancreatic hemorrhage and arteriosclerosis of the splenic artery. The spleen was grossly and microscopically normal.

As far as I am aware this is the first report of a ruptured splenic-artery aneurysm complicating the postoperative course of another abdominal but unrelated operation. At the time of the first re-exploration the presence of small blood clots in the gastrocolic ligament should have pointed to the possibility of hemorrhage into the lesser omental bursa. The hemangioma of the liver, a coincidental finding, confused the picture at the time. Tennent and Starritt[5] have stressed the appearance of fresh blood at the foramen of Winslow and at the base of the mesocolon in these cases. Inspection of the lesser omental bursa after division of the gastrocolic ligament is indicated under these circumstances. Apparently, the aneurysm had ruptured at least twice into the lesser omental bursa before the final catastrophic hemorrhage. The rupture of these aneurysms in two stages has been described by Berger et al.,[6] Gillam[7] and others.[2,4,8] The occurrence of rupture as a postoperative complication and the hemorrhage on three occasions are unusual features of this case.

### DISCUSSION

Aneurysms of the splenic artery appear to predominate in women under the age of forty-five. Tonge[3] has concluded that the association of the disease with pregnancy is more apparent than real. In older persons the sex distribution is about equal. The average age at the time of rupture in large collected series is about forty-eight.[2] Seventy-five per cent are single aneurysms, and the majority arise at the bifurcation of the splenic artery.[4] Perhaps the single most common diagnostic aid before rupture is the x-ray film of the abdomen. An ovoid calcification is usually seen to the left of the first lumbar vertebra. Although the periphery of the shadow is sharply delineated, its center is characteristically stippled. The second most common diagnostic finding is a tumor or bruit, or

*Clinical instructor in surgery, Yale University School of Medicine, New Haven; attending surgeon, Milford and West Haven Veterans Administration hospitals.

both, in the left side of the abdomen. The symptoms are not characteristic. Before rupture the pain is usually reported in the left upper quadrant, aggravated by stooping and sometimes associated with vomiting. When rupture occurs, the pain may resemble almost any major intra-abdominal catastrophe. An aortogram may be of value if the disease runs a chronic course.

The protean manifestations after rupture can be attributed to the many sites into which the aneurysm may rupture. The most common, of course, is the lesser peritoneal sac. Blood may also dissect secondarily into the major peritoneal sac, the retroperitoneal tissues and the lumen of the stomach and the colon, massive gastrointestinal hemorrhage being the major symptom in the last-named organs. Although Lennie and Sheehan[9] have recommended ligation of the splenic artery, with consequent aseptic necrosis of the spleen, such a procedure should be reserved as a second choice to splenectomy.

The pathogenesis of the condition is of four major types. The commonest cause (60 per cent) is arteriosclerosis. Mycotic aneurysms have been found to be a third as common, and congenital aneurysms were found in a seventh of the cases collected by Cosgrove et al.[2] Among the miscellaneous cases are those associated with trauma and with diseases causing enlargement of the spleen. Holman[10] recently proposed the theory that a limited segmental stenosis of an artery due to an atherosclerotic plaque may produce eddies of alternating high and low pressure, whose repeated impacts may result in aneurysmal dilatation of the artery distal to the arteriosclerotic segment. Zeluff and Parsonnet[11] believe that in congenital cases the muscularis of the parent vessel fails to join with that of the branch artery during development.

Just how great a part trauma plays in splenic-artery-aneurysm rupture is difficult to estimate. In the case reported above, this factor was considered seriously because the patient had been in a minor automobile accident three weeks before the onset of the illness. The pathologist was unable to prove that any part of the hemorrhage was due to trauma sustained five weeks previously. This report and the absence of blood in the peritoneal cavity at the time of the original exploration lend support to the theory that arteriosclerosis rather than trauma is a precipitating factor in rupture of splenic-artery aneurysms.

### Summary and Conclusions

A case of rupture of an aneurysm of the splenic artery that occurred as a postoperative complication is presented. Successful control of the aneurysm after splenectomy with partial pancreatectomy was obtained.

The pathogenesis, symptoms, diagnosis and treatment of this disease are discussed.

The only treatment is immediate splenectomy and proximal ligation of the splenic artery.

This case appears to be the sixth successful outcome after major rupture of a splenic-artery aneurysm.

### References

1. Palmer, T. H. Aneurysms of splenic artery. *New Eng. J. Med.* 243:969-993, 1950.
2. Cosgrove, G. E., Jr., Watts, J. C., and Kaump, D. H. Spontaneous rupture of splenic arterial aneurysms. *Am. J. Clin. Path.* 17:372-382, 1947.
3. Tonge, J. I. Aneurysms of splenic artery, with report of 2 cases and review of literature. *M. J. Australia* 2:119-122, 1948.
4. Dobson, L., Morse, D., and Covert, J. Aneurysm of splenic artery. *Stanford M. Bull.* 5:39-42, 1947.
5. Tennent, R. A., and Starritt, A. Case of rupture of aneurysm of splenic artery during pregnancy. *Glasgow M. J.* 31:465, 1950.
6. Berger, J. S. Forsee, J. H., and Furst, J. N. Splenic aneurysm. *Ann. Surg.* 127:108-110, 1953.
7. Gillam, J. F. E. Ruptured aneurysm of splenic artery during pregnancy. *Brit. M. J.* 1:69, 1942.
8. Sherwin, B., and Gordimer, H. Aneurysm of splenic artery: report of 2 cases. *Ann. Surg.* 131:599-603, 1950.
9. Lennie, R. A., and Sheehan, H. L. Splenic renal aneurysms complicating pregnancy. *J. Obst. & Gynaec. Brit. Emp.* 49:426-436, 1942.
10. Holman, E. "On circumscribed dilation of artery immediately distal to partially occluding band": poststenotic dilatation. *Surgery* 36:3-24, 1954.
11. Zeluff, G. W., and Parsonnet, V. Ruptured aneurysm of splenic artery: case report with discussion. *Ann. Int. Med.* 35:437-443, 1951.

---

## SERGEANT PELLENS'S CONTRIBUTION

John F. Holmes, M.D.

MANCHESTER, NEW HAMPSHIRE

SEVERAL years ago, at the Moore General Hospital in Grasmere, New Hampshire, an orderly, Belgian-born, by the name of Constant Pellens, had his attention called to the frequent confusion at the time of operation in deciding definitely on which side a previously diagnosed hernia was located. Also, in operations for varicose veins he noted the difficulty in locating a section of vein when the patient was in a recumbent position. This section was perfectly apparent when the patient was upright. The locations were further obscured by the preoperative application of certain sterilizing solutions such as Metaphen, Merthiolate and Zephiran.

Constant Pellens sought to be of help in this situation. He put together iodine and glycerin in equal parts, and sterilized the mixture and applied it to the skin areas where operation was contemplated after the parts had been identified and shaved. This left a brown stain, which remained on the skin and was perfectly apparent and showed through the sterilizing solution.

As an operating surgeon, I considered this method of marking the area of great convenience with no ill effects such as localized infection or postoperative complications. Several times I promised Mr. Pellens to report his findings. Meanwhile, he served in the Coast Artillery during World War I with the rank of sergeant. In this war his mother and brother were lost in Europe. In World War II he was with the Thirty-Ninth General Hospital Corps, better known as the Yale Unit, serving in the Pacific. In both wars he acquitted himself with honor. While in Auck-

land, New Zealand, he became fascinated by the art of the Maoris, an ancient Polynesian tribe that originated in and about the Hawaiian Islands. Not only did he master the carving and decoration of Maori art symbols but also he used it as occupational therapy for the battle-fatigued and injured soldiers who came under his care at the Thirty-Ninth General Hospital.

Constant Pellens is again a valuable and willing worker at the Moore General Hospital in the midst of appreciative friends. He still practices the Maori art. He is past commander of the Wesley Wyman Post, No. 16, of Goffstown, and a member of the 40 and 8 and the Veterans of Foreign Wars besides taking an active interest in local civic affairs.

---

## CASE RECORDS
### OF THE
## MASSACHUSETTS GENERAL HOSPITAL

### Weekly Clinicopathological Exercises

FOUNDED BY RICHARD C. CABOT

BENJAMIN CASTLEMAN, M.D., *Editor*

VIRGINIA W. TOWNE, *Assistant Editor*

---

### CASE 41191

#### PRESENTATION OF CASE

A fifty-eight-year-old nurse entered the hospital because of an abdominal mass.

For seven months the patient had been aware of a hard mass in the left lower side of the abdomen, which, when first felt, was about 1 cm. in diameter but which had enlarged to about 3 cm. in diameter. She had noticed that manual pressure on the mass produced discomfort in the lower abdomen. For the previous two or three weeks she had been very nervous over the thought that she might have a cancer and consequently had been eating poorly. For about a year and a half she had had frank eructations of increasing frequency, and for two months there had been some substernal burning. There was no history of pain in the upper abdomen, nausea, vomiting, melena or jaundice.

Twenty-five years before admission she had been in a sanatorium for two years for pulmonary tuberculosis; there had been no known recurrences of this condition. The last x-ray examination of the chest during the past year had been negative. There had been a cessation of menses eight years previously, with no subsequent vaginal bleeding. She had received no hormones. She had experienced moderate urinary frequency, with occasional urgency. Varicose veins of the legs had been treated in the past by injections.

Physical examination revealed a well developed and well nourished, healthy appearing woman. The head, chest and heart were normal except for a Grade 1 soft, blowing systolic murmur at the apex. On abdominal examination the lower border of the liver was barely palpable and was firm and smooth. The spleen and kidneys could not be felt. There were bilateral masses in the lower abdomen. The one on the right was firm, fixed, slightly nodular and about the size of a lemon, and lay deep in the right iliac fossa. The larger mass, which was on the left, seemed to rise out of the iliac fossa, extended halfway to the umbilicus and lay close to the midline in the upper portion; it was distinctly nodular, was somewhat movable and had the size and general shape of a banana. Pelvic examination revealed a normal cervix. The fundus could not be identified separately from the pelvic mass on the left, which was intimately adherent to it in the region of the left adnexa. The mass on the right was also palpable bimanually and was relatively immobile against the right pelvic wall but not as intimately adherent to the uterus. Behind the cervix in the cul-de-sac a firm nodular area several centimeters in diameter was felt. Rectal examination confirmed the vaginal findings but showed no intrinsic rectal lesion.

The temperature was 98.6°F., the pulse 70, and the respirations 20. The blood pressure was 150 systolic, 95 diastolic.

The urine was cloudy amber, had a specific gravity of 1.034 and gave negative tests for albumin, sugar and bile; the sediment contained 1 red cell, 3 white cells and 3 epithelial casts per high-power field. Examination of the blood showed a hemoglobin of 13.8 gm. per 100 cc. and a white-cell count of 7400, with 80 per cent neutrophils. The prothrombin time was 70 per cent of normal, and the total protein 8.1 gm. per 100 cc. On the second hospital day the white-cell count was 15,000, with 85 per cent neutrophils. A vaginal cytologic smear was negative for tumor cells.

An x-ray film of the chest demonstrated old calcified scars at the right apex as well as calcified nodes at the right-lung root and some pleural thickening on the right side. No active pulmonary disease was noted. An intravenous pyelogram disclosed kidneys of normal size, position and shape. The right renal pelvis and calyxes appeared more plump than the left, with no significant evidence of hydronephrosis and no demonstrable point of obstruction. The urinary bladder

was normal. The lower ureters were not adequately visualized, but there was nothing to suggest that they were impinged upon. A vaguely defined soft-tissue density was seen overshadowing the right and left aspects of the pelvis. A barium-enema examination showed good filling of the large bowel. The proximal portions of the sigmoid and terminal ileum were displaced somewhat superiorly, but no intrinsic disease of either small or large bowel was seen (Fig. 1). An upper gastrointestinal series was normal.

An operation was performed on the fourth hospital day.

## Differential Diagnosis

Dr. Howard Ulfelder*: This protocol describes a patient who came to the hospital essentially without complaint except for the presence of a hard mass in the left lower part of the abdomen, which she thought had grown slowly in size over the previous seven months.

We are told that she actually had two masses, one on the right side and one on the left. They are described as being of about the same consistence and nodularity. I think I am justified in assuming that they were of the same nature, although the possibility that they were unrelated is always present. Were they abdominal or pelvic in origin? Their location in itself will not tell us, and the report of the physical examination also does not settle this question since the mass on the right appears to have been almost entirely an abdominal tumor, whereas the one on the left is described as having been easily felt also on pelvic examination and apparently adherent to or a part of the uterus in the region of the left cornu.

I believe I can state at the outset that these tumors were either neoplastic or inflammatory. To me inflammation seems unlikely in the absence of fever, leukocytosis, significant tenderness or evidence of peritonitis, recent or in the past. The possibility of tuberculosis is raised by the past history, but this also seems unlikely in view of the negative findings otherwise. I shall at this point restrict my search to neoplasm, benign or malignant, and since I am unable to decide where the primary location may have been, I shall next follow the procedure that was obviously used by the clinician in this case and make a search through the various viscera for some evidence of localization. The patient gave a history of mild indigestion, which certainly warranted further study, although the symptoms were no more than one might find in the presence of the masses themselves. May I see the x-ray films? I am particularly interested, of course, in the barium-enema examination and intravenous pyelogram.

Dr. John F. Gibbons: The chest films show calcified tuberculous scars in the right upper lobe. Otherwise, no significant abnormality is seen. The films of the pyelogram show that the right renal collecting system is slightly fuller than the left, but there is no definite evidence of ureteral obstruction or other abnormal involvement of the urinary passages. The upper gastrointestinal study demonstrates nothing remarkable in the esophagus, stomach or duodenum.

The pertinent radiographic findings are seen on the barium-enema examination. The fluoroscopist noted that the cecum and the most terminal portion of the ileum were displaced somewhat medially and anteriorly (Fig. 1). Likewise, there was some upward displacement of the lowermost portion of the descending colon. There was no evidence of intrinsic abnormality in the large bowel or ileum, and the appendix was noted to be partly filled on films made after evacuation. There are no calcifications in the pelvis or abdomen, but there is a vague density on the left side in the bony pelvis, which is probably due to the palpable abdominal mass on the left side.

Figure 1. *Postevacuation Roentgenogram of Barium-Enema Examination.*

*There is upward displacement of the sigmoid, cecum and terminal ileum secondary to the masses in the lower abdomen and pelvis (arrows). The appendix is filled (lower arrow on right). Residual contrast medium from the pyelogram done that morning is seen in the renal calyxes.*

Dr. Ulfelder: It is apparent that the radiologist can only help define the present location, size and mobility of these masses but has not been able to detect a primary lesion in any of the organs studied and reported. The masses were not in contact with each other but were apparently fixed in their positions so that mobility was very limited and the adjacent organs were displaced without being invaded. We can be certain that the tumors had been present for at least seven months, but, even at the time of onset, I can surmise that the patient felt only the tip of the

*Visiting surgeon, Massachusetts General Hospital.

mass in the left lower quadrant and since this had increased perhaps three times in size over the seven-month interval, I am probably safe in assuming that the basic neoplasm was slowly growing and had probably been present much longer than she had been aware of it.

The description of the physical examination makes any significant amount of ascitic fluid unlikely. The evidence so far is more in favor of a benign than of a malignant neoplasm. This seems even more true if one can assume that the intestinal tract, the urinary apparatus, the cervix and the endometrium can reasonably be excluded as the primary site for cancer in this case. In fact a lymphoma primary in lymph nodes is about the only malignant condition that I believe could produce this picture.

The nonmalignant neoplasms that might produce this picture are very few. Endometriosis can be ruled out because of the eight-year postmenopausal interval without estrogen therapy; bilateral benign ovarian tumors must seriously be considered, although the amount of fixation present in this case is not a usual finding. There are two observations in this particular case that appear to me to be significant. The first is the fact that the mass on the right side by x-ray examination was quite fixed in its position and displaced the cecum and appendix forward and somewhat medially without in any way involving their walls. The other finding of interest is the nodularity palpable in the pouch of Douglas on rectal examination that is described as though it were separate from the large masses higher up. The findings described suggest the possibility of a disseminated condition although I have already put myself on record in favor of a nonmalignant tumor. Perhaps a word should be interjected here about the question of metastasis from some other primary site. The possibility of Krukenberg tumors of the ovary was obviously in the clinician's mind when an upper gastrointestinal series was ordered. Nothing was found to suggest that the patient might have had a primary gastric carcinoma, and the duodenum showed nothing that was consistent with carcinoma of either the gall bladder or the pancreas.

I have narrowed my search down now to nonmalignant neoplasms that may be found in the pelvis or lower abdomen and that may occur either in multiple sites or as a disseminated condition. The carcinoid tumor suggests itself as a strong candidate to fulfill these conditions, but I favor somewhat more strongly the condition known as pseudomyxoma peritonei, in which a primary nonmalignant mucus-producing tumor may arise in the ovary or in the appendix with the gradual appearance of daughter tumors on nearby peritoneal surfaces. The presence of the mass so intimately associated with and so fixed in the region of the cecum and appendix in this case makes me believe that the primary tumor was in this area and that the secondary manifestations had produced the larger mass in the left iliac fossa and the nodules in the posterior cul-de-sac.

### Clinical Diagnosis

Primary carcinoma of ovary, with bilateral involvement and cul-de-sac metastasis.

### Dr. Howard Ulfelder's Diagnosis

Pseudomyxoma peritonei from appendix.

### Anatomical Diagnosis

*Malignant carcinoid of appendix, with extension through serosa into periappendiceal fat and omentum.*

### Pathological Discussion

Dr. Edgar B. Taft: Dr. Green, you operated on this patient. Will you tell us your findings?

Dr. Thomas H. Green: Dr. Ulfelder has presented a concise and illuminating discussion of this interesting case, in which there were few if any clues to the ultimate diagnosis. When I first saw this woman I believed that she was probably suffering from a primary ovarian carcinoma with bilateral involvement and considerable pelvic spread. X-ray studies yielded no information inconsistent with that diagnosis, and that was the final preoperative impression.

When the abdomen was opened we were immediately confronted by the mass on the left, which proved to be a wad of omentum, studded with metastatic nodules and adherent in the pelvis. To clarify the situation it was first necessary to resect the omentum completely, beginning above all gross disease at the level of the transverse colon. When this had been accomplished, except for an area of adherence to the uterus, it was finally possible to visualize the pelvic organs. All these structures were perfectly normal. The ovaries, in particular, were small and atrophic, and obviously not the site of primary disease. Further abdominal exploration showed no abnormalities of the liver, spleen, kidneys, stomach, duodenum, pancreas or gall bladder. However, there were many enlarged, hard lymph nodes along the celiac axis and underlying para-aortic region, as well as a small peritoneal nodule in the right subhepatic fossa, one in the mesosigmoid and the one in the cul-de-sac felt preoperatively on pelvic examination.

The omentum was excised from the uterus and removed, and the remaining mass in the right iliac fossa was exposed. At first this seemed to represent another nodular collection of metastases adherent to the cecum in the region of the common and external iliac lymph nodes. But when the tumor mass was mobilized from the pelvic wall it became obvious that here was the primary lesion at last, arising either in the very bottom of the cecal pouch or in the appendix, both of which were extensively surrounded and involved by tumor.

In spite of the dissemination of the disease it was elected to perform a right-sided colectomy, primarily

because the dangers of perforation of the cecum or obstruction at the ileocecal valve in the near future seemed very real. Furthermore, in the face of what seemed to be a slowly growing tumor, the psychologic benefit to be obtained by excision of both the lumps that the patient herself could feel seemed well worth while, in addition to any possible effect that removal of the primary growth might have on the residual disease.

DR. TAFT: We received the specimens as Dr. Green has outlined: a large piece of omentum, which was studded with six nodules of tumor ranging from 0.5 to 1.8 cm. in diameter and a segment of the intestinal tract consisting of the distal 11.5 cm. of ileum and the cecum and 11.0 cm. of ascending colon. The mucosa and wall of the bowel were unremarkable. Lightly adherent by thin fibrous adhesions to the tip of the cecum was an encapsulated, lobulated tumor nodule 2.5 cm. in diameter. The appendix wound over the surface of this nodule, and the tip of the appendix blended indistinguishably with the tumor. On section the tip of the appendix and all the tumor nodules were composed of firm, pale-yellow tissue streaked with fine white lines. The appendix measured 3.5 cm. in length and proximal to the tumor was not unusual.

Microscopical examination of the tumor showed a typical carcinoid or argentaffinoma of the appendix. Its malignancy was attested by the metastatic lesions in the omentum. As everyone knows, carcinoids of the appendix are rarely malignant; in fact they are usually incidental findings at operation or autopsy. On the other hand carcinoids of the small bowel are frequently malignant; in fact they constitute more than 20 per cent of malignant neoplasms of the small bowel according to Pearson and Fitzgerald,* who reported the presence of metastases in 16 of 42 non-appendiceal carcinoids; they found no metastases in 98 appendiceal carcinoids. In their review of the literature they reported that of 68 malignant carcinoids 50 were from the small bowel and 14 from the appendix. This case was discussed because of the unusual features that it presented. Dr. Ulfelder is to be congratulated for his excellent discussion of a difficult problem, even to the point of mentioning the correct diagnosis.

DR. GREEN: The postoperative course was uneventful, and the patient was discharged on the eighteenth hospital day. The possibility of radiation therapy to the residual disease was considered but, since it is generally accepted that carcinoid tumors are not radiosensitive, this did not seem worth while. In view of the fact that a number of patients with malignant carcinoids are reported to have lived many years even in the face of residual disease, it is possible that a "second-look" operation at some future time will have more to offer, if an obvious recurrence appears.

*Pearson, C. M., and Fitzgerald, P. J. Carcinoid tumors — reemphasis of their malignant nature: review of 140 cases. *Cancer* 2: 1005-1026, 1949.

## CASE 41192

### PRESENTATION OF CASE

A fifty-eight-year-old nurse was readmitted to the hospital nine days after discharge from the first admission (published as Case 41191, — the first case in this issue, — this information being given to the discusser) with complaints of malaise, aches and pains and fever.

After discharge the patient felt well and had a good appetite; her bowels functioned well, and she regained strength. Two or three days before readmission, she noted the onset of malaise, aches and pains and frontal and retro-orbital headaches. She experienced a pleuritic type of pain in the left side of the chest that lasted only a few hours and an aching pain in the right side of the abdomen that was accompanied by cramps. There was constipation, but no nausea, vomiting, diarrhea or melena. She had a temperature of 100.5 to 101°F. accompanied by sweating, but without chills.

Physical examination revealed a well developed, well nourished woman in no acute distress, but pale, hot and sweating. The head, chest and heart were normal except for a precordial Grade 1 systolic murmur. The lower abdomen showed a well healed, nontender scar in the midline. The abdomen was soft and slightly distended. There was slight tenderness in the right lower part of the abdomen, but there were no masses or spasm. Pelvic and rectal examinations were negative except for the presence of a nodular mass in the cul-de-sac, which had not changed since the previous admission.

The temperature was 101°F., the pulse 92, and the respirations 18. The blood pressure was 140 systolic, 90 diastolic.

The urine was cloudy, amber and acid, had a specific gravity of 1.012 and gave a + test for albumin; the sediment contained 2 red cells, 8 white cells and 5 epithelial cells per high-power field. The hemoglobin was 13 gm. per 100 cc., and the white-cell count 17,400.

A plain film of the abdomen revealed a moderate amount of gas in the large bowel, without evidence of abnormal distention. Gas was observed within the rectum. A film of the chest showed no appreciable change from the preoperative film except for a possible, minute amount of fluid in the left pleural space.

On the second hospital day a tender, enlarged liver was palpated, 1 handbreadth below the right costal margin. There was no mass beneath it to suggest a gall bladder. There was tenderness on percussion of the costal margin. The abdomen below the liver was nontender and contained no masses. The spleen was not palpable. Fluoroscopy on the third hospital day showed limitation of movement of the right leaf of the diaphragm that was probably due to pleural thickening. No abnormal collection of air was seen below the diaphragm, and there was no evidence of subphrenic abscess. On the fifth hospital day an ab-

dominal film demonstrated that the liver had increased greatly in size since admission, now reaching the iliac crest and causing considerable downward displacement of the hepatic flexure. In a film taken in the left lateral decubitus position there seemed to be a small pocket of air inferior to the right leaf of the diaphragm laterally (Fig. 1). An origin of this air within the lung itself could not be excluded, however. On the seventh hospital day films taken after intravenous administration of Thorotrast revealed enlargement of the spleen to about twice its normal size. The liver was now felt to be only questionably enlarged. There was no evidence of a subdiaphragmatic collection of fluid. However, a smooth mass deforming the superior aspect of the proximal transverse colon was delineated in relation to the lower edge of the liver on the right (Fig. 2).

FIGURE 1. *Film of the Abdomen Taken in the Left Lateral Decubitus Position, Showing a Large Mass Indistinguishable from the Liver.*
*There is extrinsic pressure on the superior aspect of the hepatic flexure of the colon.*

Additional laboratory data revealed a white-cell count of 14,200, with 90 per cent neutrophils. The urinary urobilinogen was 6.6 Ehrlich units in two hours; cephalin flocculation was negative in twenty-four and + in forty-eight hours, and the alkaline phosphatase was 4 units on the second hospital day and 9.2 units per 100 cc. on the fifth hospital day, the serum amylase 2 Russell units per 100 cc., and the bilirubin 0.7 mg. per 100 cc.

The patient meanwhile improved symptomatically, and the temperature, which had risen to 102.5°F. with small swings early in the course, leveled off to 99 to 100°F. An operation was performed on the eighth hospital day.

## DIFFERENTIAL DIAGNOSIS

DR. GEORGE S. RICHARDSON*: In considering this case, I must first suppose that the patient's present illness was in some way related either to the previous operation or to some property of carcinoid. This was a febrile illness beginning with generalized manifestations — pain behind the eyes, headache and malaise — but for the most part remaining localized to the right upper quadrant, with the exception of the transient pleuritic pain on the left side of the chest and the minimal pleural fluid noted in the film of the chest taken on admission. The whole story suggests infection.

I think I have to ask first what could have happened as a result of the operation to bring about this state of affairs. The dangers connected with a right-sided colectomy that might lead to complications are injury to the ureter, injury to the duodenum or pancreas in the process of freeing up the ascending colon from its attachments to the posterior abdominal parietes and possibly trauma to the gall bladder. Then, of course, there is the healing process in the anastomosis between the small bowel and colon. This lay somewhere at the right end of the transverse colon immediately below the liver, which was where the complaints were localized on admission.

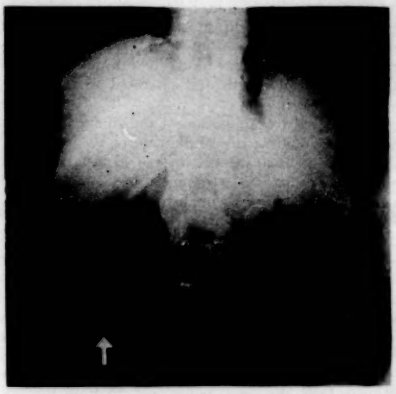

FIGURE 2. *Abdominal Film Taken Forty-Eight Hours after the Initial Injection of Thorotrast, Showing the Liver Opacified, Normal in Size and Distinctly Separate from the Large Globular Mass, Which Lies Adjacent to it Medially.*

The variability of the liver size is peculiar. It was not felt at all on admission and was not mentioned in

*Assistant in surgery, Massachusetts General Hospital.

conjunction with the reading of the first abdominal films. These showed only a patent gastrointestinal tract as evidenced by gas throughout the colon and in the rectum. On the next morning, however, the liver was tender and grossly enlarged, extending 1 handbreadth below the right costal margin, and the costal margin that overlay it was also tender. On the third hospital day the x-ray report was that the right leaf of the diaphragm was elevated. By the fifth hospital day the liver was even larger, and on the x-ray films there was a suggestion of air below the diaphragm. Apparently, the physicians were as curious about what was happening as I am, because two days later they did Thorotrast studies, being willing, apparently, to risk later sequelae of Thorotrast administration in the form of carcinogenesis, in a patient in whom carcinomatosis, even though of a low grade, had been left behind.

The question of what this large liver was is the most important one that I have to answer. It seems to me most unlikely that a liver would undergo this sort of enlargement and involution in a very short period, without changes of chemical values related to liver function, in a patient who was not ill enough to have an intrahepatic abscess or hepatitis, and in whom there was no reason for believing that there was passive congestion of the liver due to heart failure. I think that means that the disease was not primarily in the liver but somewhere else, and, of course, the Thorotrast study upheld that conclusion. I think I must take at face value the information that the exploration of the abdomen failed to reveal any abnormality in the gall bladder, pancreas, spleen and so on, and assume that the patient did not have stones in the gall bladder, that acute cholecystitis did not suddenly develop and that an impacted stone in the cystic duct was not producing an inflammatory mass below the liver that displaced the transverse colon downward and the liver upward. I think it is unlikely that the gall bladder, duodenum or ureter was injured. I shall have to ask myself these questions again as I look at the x-ray films. The liver should be well outlined in the Thorotrast study, and perhaps the kidney as well. I do not think that there was injury to the ureter, with hydronephrosis and later with infection. There would have been posterior-costovertebral-angle tenderness and a much more severe febrile course. May we look at the x-ray films?

DR. C. C. WANG: The films taken on the second admission show a large soft-tissue mass overlying the right side of the abdomen that cannot be definitely separated from the liver. There is a smooth, gentle indentation on the air-containing proximal transverse colon superiorly. There are no opaque stones within this soft-tissue mass. On all these films the outline of the right kidney is clearly seen and the right-psoas-muscle shadow is faintly visible. Examination of the abdomen a week later shows no significant change in the downward displacement of the transverse colon. After intravenous injection of Thorotrast the liver and spleen are well outlined and appear normal in size and shape. The previously described soft-tissue mass is again seen and does not appear to be connected with the liver or composed of liver elements.

DR. RICHARDSON: Was there fluid in the left pleural space in later films of the chest?

DR. WANG: No.

DR. RICHARDSON: Do you think that the liver had actually increased in size during the patient's hospital course?

DR. WANG: From the x-ray films alone I do not think the liver had increased in size.

DR. RICHARDSON: Has the level of the right leaf of the diaphragm changed significantly?

DR. WANG: No; except that there is a small quantity of free air beneath the right leaf of the diaphragm.

DR. RICHARDSON: You think that that actually is air under the diaphragm rather than air in the lungs?

DR. WANG: I think it is probably air beneath the diaphragm; it disappears in subsequent examinations.

DR. RICHARDSON: Is the kidney displaced downward?

DR. WANG: Both kidneys are in fairly normal position.

DR. RICHARDSON: Do you think the spleen is enlarged in the Thorotrast film?

DR. WANG: If it is enlarged the enlargement is very slight.

DR. RICHARDSON: I think the x-ray films clear away some of the difficulties and add a few grains of salt to the idea that the liver or the mass was as labile as the protocol implied. I think I can disregard the splenic enlargement. Having decided that the patient had a septic process, I think that I can reasonably assume that in the region of the anastomosis, lying just below the liver, there was contamination at operation and that after a latent period an abscess formed in the right infrahepatic space. The infection was probably a low-grade, smoldering process, the large proportion of the mass being made up of the transverse mesocolon and fatty tissue in the region of the gall bladder, with only a relatively small amount of liquid pus, as so often happens in intra-abdominal abscesses. The organism itself may have been of low grade, like a *Staphylococcus albus*. Subphrenic abscesses are often ignored. In one series of patients[1] the average duration of the disease before the diagnosis was made was four months; the abscesses have been diagnosed after much longer latent periods. I believe that a small abscess was present in relation to the anastomosis. The anastomosis evidently was not obstructed. The patient had a few cramps, but they were hardly significant, for they were mentioned but once in the protocol and the x-ray films failed to demonstrate obstruction.

I have not accounted for the transient pleuritic pain on the left. I could account for it by some bizarre condition such as emboli from the region of an intra-abdominal abscess, which may occur oc-

casionally. The patient was not particularly ill, and on admission there was no evidence of thrombi in the leg veins, as manifested by swelling of the legs, tenderness of the calves and so on. I think I must leave that out.

I think that the marked upward displacement of the diaphragm and downward displacement of the transverse colon are consistent with a subphrenic abscess; the air beneath the diaphragm lends confirmation to that. After the Thorotrast studies demonstrated a mass the next logical step was exploration, either to drain pus or to handle whatever was found.

Recognizing that this is a clinicopathological conference and that the pathologists must receive a piece of tissue, I am inclined to consider the nature of the patient's tumor a little further. I was interested to learn in the literature on carcinoids that Gold and Grayzel[2] reported the case of a forty-four-year-old woman who had had incision and drainage of a necrotic subhepatic abscess. She died five years later of congestive heart failure. At autopsy it was quite evident that the abscess that had been drained was a necrotic metastasis of a carcinoid. It was remarked elsewhere in the literature[3] that carcinoid metastases, especially to the liver, may be hemorrhagic and may even form cysts — that is, they may be autolyzed in the center. A fifty-one-year-old man who had metastases of carcinoid in the liver had in the year and a half between the exploration and death a massive increase in the size of the liver; at death the liver weighed 15,200 gm. and was filled with hemorrhagic cystic nodules up to 20 cm. in diameter. I asked myself if it was possible that the trauma in the region of the plum-sized mass of carcinoid that lay below the liver was sufficient to make an already hemorrhagic metastasis with a cystic center undergo further autolysis or bleeding and thus produce a mass. Perhaps superimposed on the trauma was infection in the region of the suture line that was enough to produce the sequence of events. Then the piece of tissue that interested the pathologists was the original metastasis, which had been palpated before and had enlarged as the result of bleeding or sepsis or some such combination of events.

The diagnosis that I shall make is subhepatic metastasis of the carcinoid, with hemorrhage and infection.

DR. ROBERT E. SCULLY: Dr. Ulfelder did not see this patient, but he discussed her case at the previous clinicopathological conference. I wonder if he would like to comment.

DR. HOWARD ULFELDER: I thought when I had to discuss the first admission that I had been "put upon," but I think Dr. Richardson has been "put upon" even more. He is asked to arrive at a differential diagnosis of right-upper-quadrant pain and mass in a patient who possibly had any one of the usual causes or in addition may have had one of a number of unusual causes related to the previous operation or the known malignant tumor in that area. I think he has discussed it very well. I do not know whether he has made the correct diagnosis, but I wondered why he excluded the usual cause for pain and a tender mass in this area except on a statistical basis. I am thinking of cholecystitis.

DR. RICHARDSON: Cholecystitis or postoperative pancreatitis. Perhaps I was much influenced by the report that the gall bladder was normal at the previous operation; that stones were not felt is not a guarantee that they were not present. We have seen many patients who have had acute cholecystitis postoperatively that sometimes has been masked by antibiotic therapy. Often, the first sign of the disease is the palpation of the mass. It is conceivable that the patient had antibiotics and went home, and after a latent period an already present inflammation became evident. The story that she gave is not at all incompatible with cholecystitis. However, I have taken what was found at the previous operation as given, and have excluded cholecystitis on that basis.

I should have mentioned the pancreas because the mobilization of it, which might well have occurred during the operation, could have given rise to a low-grade pancreatitis, which notoriously produces abscesses in the region of the transverse mesocolon, below the liver. These abscesses may be almost entirely solid, with fat necrosis and edema, and are likely to be associated with low-grade fever, such as this patient had. The amylase was not elevated; the mass was confined to the right intrahepatic space; there was no evidence of duodenal deformity, and she never vomited — I think she would have vomited if the mass was in the head of the pancreas; therefore, I did not consider it.

DR. SCULLY: Dr. Green took care of this patient. Perhaps he will comment.

DR. THOMAS H. GREEN: I agree with Dr. Richardson that he had a number of possible postoperative complications as well as the usual primary diseases in the right upper quadrant to consider. We were puzzled, as he was, by some of the data in the case. I do not know whether it is more difficult to have all the data at once or to receive them bit by bit, day by day. We were first concerned with the possibility of postoperative sepsis in the region of the previous operative procedure. We believed, as we followed the patient closely by repeated examination and several fluoroscopies of the chest, that a subphrenic abscess was at the bottom of her trouble; several times the radiologists were almost willing to help us make that diagnosis. We thought that an exploration was going to be necessary, but still wondered whether the abscess lay above or below the liver. Because of our inability to prove conclusively that this was a subphrenic process we finally administered Thorotrast, which helped us a great deal. This was one of those ideal situations in which Thorotrast could be of great help, and long-term sequelae of its use needed not concern us too

seriously. We finally decided that this represented either a subhepatic abscess or acute inflammation of the gall bladder, although we were reluctant to make the latter the primary diagnosis because of the negative findings in the gall bladder at the first operation.

### Clinical Diagnosis

?Subhepatic abscess.
?Acute cholecystitis.

### Dr. George S. Richardson's Diagnosis

Subhepatic metastasis of carcinoid, with hemorrhage and infection.

### Anatomical Diagnoses

*Acute cholecystitis, healing.*
Cholelithiasis.

### Pathological Discussion

Dr. Green: On exploration a large, banana-shaped, acutely obstructed and inflamed gall bladder was found and removed. The bile was not quite white but certainly had been sealed within the gall bladder for a number of days. Four very small calculi of the calcium bilirubinate variety were present, one of which had become impacted in a tiny cystic duct. We did not feel too badly about not having felt gallstones only a few millimeters in size at the time of the previous laparotomy. The patient is convalescing uneventfully and is about ready to go home. Although we had felt lymph nodes along the aorta during the previous exploration, interestingly enough we now could find no evidence of carcinoid in the right upper quadrant, this being the first time we had visualized this area.

Dr. Scully: Pathological study of the gall bladder showed the changes of a healing acute cholecystitis; its wall was greatly thickened by very young connective tissue. There was no evidence of tumor in the specimen.

### References

1. Hochberg, L. A. Diagnostic criteria for subphrenic abscess based upon study of 139 cases. *Ann. Int. Med.* 17:183-205, 1942.
2. Gold, I. E., and Grayzel, D. M. Multiple argentaffinomas in ileum, with metastases in lymph nodes and in liver. *Am. J. Surg.* 60:144-148, 1943.
3. Pearson, C. M., and Fitzgerald, P. J. Carcinoid tumors — re-emphasis of their malignant nature: review of 140 cases. *Cancer* 2: 1005-1026, 1949.

---

Massachusetts Physicians Art Society

38. *"As a Lobster Boiled—"*

*Exhibited at Annual Meeting, Massachusetts Medical Society, 1954*

*Oil Painting by*

Joseph A. Lundy, M.D.

Physician to the Worcester City and Hahneman hospitals

# The New England Journal of Medicine

Official Organ of
THE MASSACHUSETTS MEDICAL SOCIETY

OWNED BY THE SOCIETY AND
PUBLISHED WEEKLY UNDER THE JURISDICTION OF THE
COMMITTEE ON PUBLICATIONS



Richard M. Smith, M.D., *Chairman*
James P. O'Hare, M.D. — Richard E. Alt, M.D.
Oliver Cope, M.D. — James M. Faulkner, M.D.

Joseph Garland, M.D., EDITOR
ASSOCIATE EDITORS
Thomas H. Lanman, M.D. — Donald Munro, M.D.
Theodore H. Ingalls, M.D.

Clara D. Davies, EXECUTIVE EDITOR
Robert O'Leary, ASSISTANT EDITOR
James F. Ballard, BOOK REVIEW EDITOR
Milton C. Paige, Jr., BUSINESS MANAGER

EDITORIAL BOARD
Henry R. Viets, M.D. — Benjamin Castleman, M.D.
Robert M. Green, M.D. — J. Englebert Dunphy, M.D.
Dwight O'Hara, M.D. — Robert W. Buck, M.D.
Fletcher H. Colby, M.D. — Herrman L. Blumgart, M.D.
Robert L. Goodale, M.D. — Frank N. Allan, M.D.
Chester M. Jones, M.D. — Harvey A. Kelly, M.D.
Harvey R. Morrison, M.D. — Langdon Parsons, M.D.
Maxwell Finland, M.D. — Mark Aisner, M.D.
Vernon P. Williams, M.D. — Walter F. Lever, M.D.



SUBSCRIPTION TERMS: $8.00 per year in advance, postage paid, for the United States (first-year interns and medical students, $5.00 per year); Canada, $9.00 per year (Boston funds); foreign, $10.50 per year. Long-term rates: United States, 2 years $15.00, 3 years $22.00; Canada, 2 years $17.00, 3 years $25.00; foreign, 2 years $20.00, 3 years $29.50.

MICROFILM volumes available to regular subscribers through University Microfilms, 313 N. First Street, Ann Arbor, Michigan.

MATERIAL, other than original articles, should be received not later than noon on Thursday, three weeks before date of publication.

THE JOURNAL does not hold itself responsible for statements made by any contributor.

COMMUNICATIONS should be addressed to the *New England Journal of Medicine*, 8 Fenway, Boston 15, Massachusetts. Telephone KE 6-2094.


MANUSCRIPTS, including references or bibliography, should be typewritten double spaced and submitted as original copy. References should conform to the style of the *Quarterly Cumulative Index Medicus* (listing name and initials of author, title of article, journal, volume number, first and last pages and year), and should be cited numerically in the order in which they appear in the text; the number should be limited to the absolute minimum.

ILLUSTRATIONS are reproduced as half tones and zinc etchings. Photographs must be distinct, and drawings done in black ink on white paper and each properly labeled.

MATERIAL printed in the *New England Journal of Medicine* is covered by copyright. Articles are accepted for consideration with the understanding that they are contributed for publication solely in this journal.

## PREVENTION OF RECURRENCES OF RHEUMATIC FEVER

IN recent years considerable data have accumulated to indicate that the prevention of recrudescences or recurrences of rheumatic fever, and hence a reduction in the occurrence or progression of rheumatic heart disease, may be achieved by the administration of antimicrobial agents that eliminate and prevent further implantation of Group A hemolytic streptococci and prevent or greatly reduce the occurrence of infections with these organisms. Because of the marked susceptibility of the Group A streptococci to penicillin, and since penicillin resistance in such organisms has not been encountered, this antibiotic is conceded to be the most effective agent for prevention of these infections. For the same reasons, both oral and repository preparations, which yield lower blood levels than frequent injections of soluble preparations, accomplish this purpose.

From a practical point of view penicillin preparations for oral use have necessarily been chosen for such prophylaxis, and this has also had the advantage of fewer hypersensitivity reactions. The availability of a repository preparation that, in a single injection, could be relied upon effectively to eliminate Group A streptococci and prevent infections with such organisms for several weeks has necessitated a re-evaluation of the dosage forms most appropriate for this purpose. The demonstration that a single dose of benzathine penicillin G (dibenzylethylenediamine dipenicillin G, sometimes referred to as DBED, or under the trade name Bicillin), given each month provides fully as adequate protection as continuous daily oral administration and offers more effective assurance of maintenance of therapy, suggests that this may now be the method of choice in the prophylaxis of children with rheumatic heart disease against infections with the Group A streptococci.

In this issue of the *Journal* Stollerman and his coworkers have brought their experiences with this method of prophylaxis up to date. The data presented, as well as those of others collected over a shorter period,[1] confirm the effectiveness and relatively low toxicity of this form of penicillin for this particular purpose when given intramuscularly in monthly doses of 1,200,000 units. The effectiveness of single doses in eliminating the carrier state for Group A streptococci in young recruits has also been demonstrated,[2] and the possibility of preventing rheumatic fever by treatment of acute streptococcal pharyngitis with such a dose has been suggested.[3] The present study, however, cannot be regarded as demonstrating the superiority of this mode of prophylaxis of rheumatic fever over any other, since no valid controls were carried out on the same type of patients under identical conditions and comparisons with materials studied by others are often misleading.

The results must be interpreted with caution until more experience over longer periods has accumulated,

particularly regarding potential toxicity. In the first place there is reason to believe that sensitization by the use of benzathine penicillin may occur considerably more often than the 1 per cent indicated from the data presented by Stollerman et al. Thus, more than 5 per cent of young recruits who denied having any previous history of penicillin reactions had urticaria, angioneurotic edema or joint symptoms without either of these manifestations after a single intramuscular dose of 1,200,000 units of benzathine penicillin. Most of these occurred during the second week after the injections, and several were considered severe enough to warrant treatment with ACTH or cortisone. The less frequent sensitization reactions in the rheumatic subjects may be related to their lower age and the likelihood that fewer of them have had previous experience with penicillin. Moreover, the patients with rheumatic heart disease were continuously under the effect of penicillin, and serious hypersensitivity may not become apparent until the penicillin has been completely eliminated.

Unfortunately, reports are not available on studies of reactions to administration of penicillin in any form to patients who had received benzathine penicillin long enough to have completely eliminated the drug. It is well known that repository forms of antigens have been used to increase their antigenicity, and the longer they persist at the local site, the greater and more persistent the antibody response is supposed to be. It will be recalled that the large number of serious and even fatal anaphylactoid reactions to procaine penicillin were recognized only after that agent had been in wide use for a considerable period. Similar severe reactions were also encountered with unusual frequency with the use of penethamate (Neopenil), another insoluble respository preparation of penicillin. Inadvertent intravenous injection has been considered a possible cause of some of these anaphylactoid reactions.

In this connection it is well to note that 1 patient was recently observed to have persistent urticaria for at least three months, in spite of cortisone therapy, after a single dose of benzathine penicillin G; there was no history of previous reactions to penicillin and the urticaria started ten days after the administration of benzathine penicillin G.[4] Another case of a severe and prolonged reaction, with urticaria, arthralgias, circulatory collapse, edema, fever, hepatomegaly and azotemia lasting more than two weeks, with remissions during cortisone therapy, was reported in a child after a single dose of 600,000 units.[5]

The local pain after injections of benzathine penicillin, noted as persisting for two or three days in many of the children, is evidence of an inflammatory reaction that also warrants study, particularly in view of the recent reports of fibrosarcomas arising at the site of injections of penicillin in sesame oil.[6] The conditions are not comparable, and this complication may be very rare. Nevertheless, the possibility must be kept in mind if local lesions arise and persist at the sites of injections.

Other notes of caution may be introduced at this point. The relatively frequent occurrence of staphylococcal infections and of other nonstreptococcal upper respiratory infections with fever and particularly the development of 2 cases of endocarditis due to *Streptococcus viridans* emphasize the limited prophylactic value of this long-acting penicillin preparation. Its effectiveness can probably be utilized only against Group A streptococci and gonococci, and perhaps also in syphilis. Whether the prophylaxis actually predisposes to or enhances the opportunity of infections with organisms resistant to the very low levels of penicillin that are maintained is a matter worth bearing in mind for evaluation of long-range results in larger numbers of cases.

Another point that needs emphasis is that the prophylactic value of benzathine penicillin G can be claimed only for the monthly intramuscular dosage used. Unfortunately, in the promotion of this product the preparations for oral administration are also alleged to be superior to the usual buffered preparations of the soluble sodium or potassium salts. This impression may be gained from some reports, but it does not stand close scrutiny of the data on which it is based. It is only reasonable to expect, from the manner in which penicillin is excreted, that the longer action of this agent, when given by mouth, must be related only to its longer sojourn in the bowel.[7] However, this longer persistence in the bowel implies that absorption of penicillin must take place at a lower level, and it is known that most of the penicillin is absorbed just after it leaves the stomach and very little if any is absorbed from the lower bowel, where most of it is destroyed. As a result the blood levels of penicillin after oral administration of benzathine penicillin G are erratic and unreliable; the peak levels are always lower, and the total duration of even the lower levels is not significantly longer than when the same number of units of soluble salts of penicillin G are given by mouth.[8,9] Since, in spite of the preference of many physicians for the intramuscular preparations, many patients may have to be given oral penicillin, the buffered sodium or potassium salts should be given preference when that route is used. There is also good evidence that sulfonamides are as effective as benzathine penicillin G by mouth in the prevention of streptococcal infections and recurrences of rheumatic fever.[10]

By the same token the oral administration of benzathine penicillin G cannot be recommended for prophylaxis against subacute bacterial endocarditis during or after dental extractions or similar procedures. Indeed, the use of the intramuscular preparation of benzathine penicillin G for this purpose may also be considered to be undesirable, and perhaps even more so than the oral dosage form. This is implied in the comments of Stollerman and his co-workers in their

discussion of the cases of subacute bacterial endocarditis that developed during the prophylactic regimen with benzathine penicillin.

### References


1. Diehl, A. M., Hamilton, T. R., Keeling, I. C., and May, J. S. Long-acting repository penicillin in prophylaxis of recurrent rheumatic fever. *J.A.M.A.* 155:1466-1470, 1954.
2. Chancey, R. L., et al. Studies of streptococcal prophylaxis comparison of oral penicillin and benzathine penicillin. *Am. J. M. Sc.* 229:165-171, 1955.
3. Chamovitz, R., Catanzaro, F. J., Stetson, C. A., and Rammelkamp, C. H., Jr. Prevention of rheumatic fever by treatment of previous streptococcal infections. I. Evaluation of benzathine penicillin G. *New Eng. J. Med.* 251:466-471, 1954.
4. Mulligan, R. F. Persistent urticaria following use of penicillin. *J.A.M.A.* 157:782, 1955.
5. Anderson, H. C. Prolonged reaction to intramuscular benzathine penicillin. *Lancet* 2:1157, 1954.
6. Goldenberg, I. S. Penicillin in sesame oil and fibrosarcoma: report of two cases. *Cancer* 7:905-909, 1954.
7. Walkenstein, S. S., Chumakow, N., and Seifter, J. Fate and sojourn of dibenzylethylenediamine $C^{14}$-dipenicillin G and $C^{14}$-penicillin G following oral and intramuscular injection. *Antibiotics & Chemother.* 4:1245-1250, 1954.
8. Wright, S. S., Purcell, E. M., Kau, E. H., and Finland, M. Penicillin G and benethacil by mouth: comparison of penicillin levels in plasma of normal men after single oral doses. *J. Lab. & Clin. Med.* 42:417-429, 1953.
9. Foltz, E. L., and Schimmel, N. H. Comparison of orally administered penicillins. I. N, N' dibenzylethylenediamine dipenicillin G. II. Procaine penicillin G. III. Potassium penicillin G. *Antibiotics & Chemother.* 3:593-599, 1953.
10. Markowitz, M., and Hemphill, W. Comparison of oral N, N' dibenzylethylenediamine dipenicillin G and sulfonamides for prevention of streptococcal infections and recurrences of rheumatic fever. In *Antibiotics Annual, 1954-1955.* Edited by H. Welch and F. Martí-Ibáñez. 1154 pp. New York: Medical Encyclopedia, Inc., 1955. Pp. 85-89.


## NATIONAL HEALTH LEGISLATION

About midway through the first session of the Eighty-fourth Congress, the Washington office of the American Medical Association last month summarized the important health legislation still pending. Six of the most controversial of these bills have also been analyzed in the current report of the Committee on National Legislation of the Massachusetts Medical Society. The leisurely pace at which they have been moving through the corridors on Capitol Hill is attributed to the fact that the present Congress has still another year and a half in which to deliberate before elections.

The Administration's modified health-reinsurance bill, carrying a minor, but probably a very minor, threat to voluntary health insurance, is actively opposed by the American Medical Association. Its chances of Congressional approval are slim, according to Gross's *Washington Report on the Medical Sciences* of April 11. In similar case is the mortgage-loan insurance bill for hospital and medical facilities, providing a federal guarantee of mortgages on such facilities, to be administered by the Department of Health, Education and Welfare. Opposed by the Association this bill also is said to have little chance for survival.

Two bills concerned with nurses' training are similarly held in disfavor. One provides for grants in aid to states to extend and improve the training of practical nurses; the other would amend Title III of the Public Health Service Act to authorize the Surgeon General to establish and maintain traineeships for the "training of professional nurses to teach or serve in administrative or supervisory capacities," and for "graduate or specialized training for doctors, engineers, nurses and other health personnel." It is this broad coverage that condemns it in the eyes of the Association.

A fifth bill, approved in principle by the American Medical Association, would amend the Public Health Service Act to authorize a single consolidated public-health grant to states in place of present separate grants, to be allotted on the basis of population, financial need and the extent of the health problems involved. The mental-health bill, to continue for five years the present pattern of grants in aid to states, would also authorize grants for special projects. This bill has the active approval of the Association.

The so-called Bricker Resolution, with its theoretically possible protective effect on the private practice of medicine, has been undergoing hearings by the Senate Judiciary Subcommittee on Constitutional Amendments. As in the last Congress, this resolution has the active support of the American Medical Association.

Of 75 titles listed by the Association's Washington office, the Association opposes 35 actively or in principle, and approves 19.

With relief the nation learns that the Post Office Department has finally consented to the repeal of the law banning the shipment of live scorpions by mail. These mischievous denizens of the Arizona desert may now travel in sting-proof plastic containers to the poisonous-animals research laboratory at Arizona State College by other means of transportation than private courier.

## DIVISION OF SPECIAL EDUCATION

The General Court of Massachusetts passed in 1954 an act establishing within the Department of Education a division of special education. This act, which amended certain chapters of the *General Laws*, specified that such a division should have a director and supervisors of the education "of children who are mentally retarded, physically handicapped, deaf or hard of hearing, blind, or with impaired vision or speech."

Further important amendments, relating to chapters 15, 69, 70 and 71, provide that the school committee of each town, acting under regulations prescribed by the Department of Education and the Department of Mental Health, shall annually ascertain the number of mentally retarded children either attending the public schools of the town or of school age. These children are classified as the educable mentally retarded, the trainable mentally retarded and the custodial mentally retarded.

It is further provided that towns in which there are more than 5 such children shall, and towns in which there are fewer than 5 may, establish special classes for

the instruction of those children who are educable and trainable, according to their capacity for education or training. Final amendments provide that any city or town having fewer than 10 mentally retarded children may, with the approval of the Department, join with other cities or towns in similar case to provide the necessary special classes, and that the parents or guardians of any child so classified may apply to the Department for a review of the determination.

The act providing for these various amendments of existing laws, establishing a division of special education and resulting in Chapter 514, has necessitated action also by the Division of Maternal and Child Health of the Department of Public Health relative to the physical examination of this new group of pupils. As has been customary, the Committee on School Health of the Massachusetts Medical Society was called on for advice; after a number of meetings and the expenditure of considerable time and effort new recommendations were brought in regarding the minimal medical history that should be obtained and the minimal physical examination that should be performed on all children in the classifications under consideration.

It was further recommended that these children be examined before entrance to school or during the first year after entrance and at intervals of either three or four years thereafter, unless more frequent examinations are indicated in any given case.

In recommending that whenever possible the child's private physician should be requested to perform this examination with its additional inquiries into the child's past history, the Committee re-emphasizes the desirability of drawing on those sources of knowledge that are available only to the the family physician.

## OLD WINE IN NEW BOTTLES

New Jersey's first medical school, the Seton Hall College of Medicine and Dentistry, will be ready to receive students in the fall of 1956, according to recent advices. It has been more than a year in the planning.

Established in the Jersey City Medical Center, considered one of the most complete and modern hospital units in the country, the school received its first grant this spring — one of $3,000 made for a period of three years by the International Academy of Proctology to found a chair in that specialty. The presentation was made by Dr. Earl Halligan, director of the Medical Center and international secretary general of the Academy, and was accepted for the School by Msgr. John McNulty, president of Seton Hall University.

On the same day, March 26, during the seventh annual meeting of the International Academy, a three-year grant was made to the new Albert Einstein College of Medicine, which will open this fall in New York's Bronx. The first project under the grant will be the establishment of a pathology-slide library consisting of pathologic tissue specimens of diseases of the colon, rectum and anus.

The Seton Hall College of Medicine and Dentistry is not strictly speaking New Jersey's first medical school since the state has at one time or another given shelter to the Hygeio-Therapeutic College at Bergen Heights, the Medical and Surgical College of the State of New Jersey, the medical school of Livingston University, at Haddonfield, and the Central University of Medicine and Science, at Jersey City. None of these institutions are listed as accepted schools in the directory of the American Medical Association.

Despite a relative scarcity in schools of medicine, New Jersey enjoys the distinction of having been the cradle of the first state medical society in the country, founded in 1766. The society as such was out of existence from 1775 to 1807; during this period the Massachusetts Medical Society was incorporated in 1781. The admirable *Journal of the Medical Society of New Jersey* celebrated its fiftieth anniversary in 1954.

---

*The Ohio State Medical Society has passed a resolution, unanimously, that "it is not derogatory to the medical profession to hold patents for surgical and dental instruments" — thereby conflicting with the code of ethics of the American Medical Association.*

Boston M. & S. J., *May 17, 1855*

---

## MASSACHUSETTS MEDICAL SOCIETY

### DEATHS

Campbell — Frederick L. Campbell, M.D., of Brighton, died on April 11. He was in his fiftieth year.

Dr. Campbell received his degree from Tufts College Medical School in 1933. He was president-elect of the Massachusetts Academy of General Practice.

He is survived by his widow, three daughters and a son.

---

Hayes — Justin E. Hayes, M.D., of Northampton, died on February 2. He was in his seventy-fourth year.

Dr. Hayes received his degree from the College of Physicians and Surgeons, Baltimore, in 1904. He was a member of the staff of the Cooley Dickinson Hospital and a trustee of the Northampton State Hospital, censor from and formerly president of Hampshire District Medical Society and a fellow of the American Medical Association.

He is survived by his widow.

---

## NOTICES

### MASSACHUSETTS MEDICO-LEGAL SOCIETY

**The annual meeting of the Massachusetts Medico-Legal Society will be held at the Hotel Statler, Boston, on Wednesday, May 18, at 2:30 p.m.**

Dr. Milton Helpern, chief medical examiner, New York City, will speak on the topic "Investigation of Violent Deaths."

## SOUTH END MEDICAL CLUB

A meeting of the South End Medical Club will be held at the headquarters of the Boston Tuberculosis Association on Tuesday, May 24, at noon.

Dr. Harry A. Derow will speak on the topic "Management of the Nephrotic Syndrome."

## GYNECOLOGY AND PSYCHIATRY PANEL

A panel discussion by the gynecology and psychiatry units on the topic "Hysterectomy: Co-operation in operation" will be held in the nurses' amphitheater, Peter Bent Brigham Hospital, on Thursday, May 19, from 2-4 p.m.

The panel will include Dr. Doris Menzer, moderator, Dr. Somers H. Sturgis, Dr. Joseph C. Sabbath, Mrs. Janet Stowell, Mrs. Harriet Robey and Mr. Thomas Plaut.

## MASSACHUSETTS PHYSICIANS ART SOCIETY

All members are reminded to prepare their art pieces for the exhibit at the Massachusetts Medical Society meeting May 17-19. Details have been sent the members. If any wish to submit art works who are not members of the Art Society, they may do so by becoming members before the exhibit.

The December 23 issue of the *Journal* contained an article on the seal of the Massachusetts Medical Society. If any members are interested in drawing another one with a new interpretation, they are encouraged to do so and to send it to the Secretary.

Any members of the Massachusetts Medical Society who are interested in joining the Physicians Art Society may do so by getting in touch with secretary-treasurer, Dr. Conrad Nobili, 34 Hancock Court, Quincy.

## INTERNATIONAL COLLEGE OF SURGEONS

The regional meeting of the Eastern Division of the International College of Surgeons will be held at the Chatham Bars Inn, Chatham, Massachusetts, July 1 through 4.

## de VILLIERS FOUNDATION GRANTS

The Robert Roesler de Villiers Foundation announces grants in aid of not more than $1,000 for research in preventive measures, control or cure of leukemia.

Qualified investigators may apply to the Robert Roesler de Villiers Foundation, Incorporated, 1172 Park Avenue, New York 28, New York, before August 1.

## SOCIETY MEETINGS AND CONFERENCES

May. Sanitary Engineering Center Training Programs. Page 122, issue of July 15.
May 13 and 14. American Association for Cleft Palate Rehabilitation. Page 461, issue of March 17.
May 13–15. American Academy of Dental Medicine. Page 554, issue of March 31.
May 17–19. Massachusetts Medical Society. Annual Meeting. Hotel Statler, Boston. Program. Pages 734-738, issue of April 28.
May 17-19. Massachusetts Physicians Art Society. Notice above.
May 17–26. Boston City Hospital House Officers' Lectures. Page 509, issue of March 24.
May 17–26. Consultation Clinics for Crippled Children in Massachusetts. Page 733, issue of April 28.
May 18. Massachusetts Medico-Legal Society. Page 827.
May 18–20. American College of Cardiology. Page 414, issue of March 10.
May 18–25. Lahey Clinic Lectures. Page 289, issue of March 17.
May 20. New England Rheumatism Society. Page 785, issue of May 5.
May 23–27. American Trudeau Society. Page 462, issue of March 17.
May 24. South End Medical Club. Notice above.
May 25–June 15. Boston State Hospital. Psychiatry Seminars. Page 461, issue of March 17.
May 29–June 2. American Society of X-Ray Technicians. Page 553, issue of March 31.
June 1–4. American Proctologic Society. Page 648, issue of April 14.
June 1–5. American College of Chest Physicians. Page 553, issue of March 31.
June 5 and 6. American Board of Physical Medicine and Rehabilitation. Page 794, issue of November 4.
June 6–10. Woman's Auxiliary to the American Medical Association. Page 647, issue of April 14.
June 7–9. United States Public Health Service Medical-Officer Examinations. Page 509, issue of March 24.
June 10–12. American Electroencephalographic Society. Page 647, issue of April 14.
June 13–15. American Neurological Association. Page 689, issue of April 21.
June 13–17. European Rheumatology Congress. Page 742, issue of April 28.
June 21–25. National Association for the Prevention of Tuberculosis. Page 540, issue of March 25.
July, August and September. Beth Israel Hospital Course. Page 509, issue of March 24.
July 1–4. International College of Surgeons. Notice above.
July 10–16. Congress of Nobel Prize Winners. Page 510, issue of March 24.
July 11–15. Symposium on Tuberculosis. Page 509, issue of March 24.
August 28–September 2. American Congress of Physical Medicine and Rehabilitation. Page 157, issue of January 27.
October 6–8. Academy of Psychosomatic Medicine. Page 509, issue of March 24.
October 22–26. American Heart Association. Scientific Session. Page 603, issue of April 7.
October 23–27. American Institute of Dental Medicine. Page 414, issue of March 10.
November 6–13. Second International Congress of Allergology. Page 157, issue of January 27.
November 19–21. American Association of Blood Banks. 8th Annual Meeting. Palmer House, Chicago, Illinois.
November 29–December 2. Interim Session of the American Medical Association, Boston.

## CALENDAR FOR THE WEEK BEGINNING THURSDAY, MAY 19

THURSDAY, MAY 19

Massachusetts Medical Society. Annual Meeting. Hotel Statler, Boston.
*8:00–8:45 a.m. Case Presentations. Joslin Clinic. Joslin Auditorium, New England Deaconess Hospital.
*8:45–9:45 a.m. Cardiac Grand Rounds. Yamins A, Beth Israel Hospital.
*9:00–10:00 a.m. Surgical Rounds. Sherman Auditorium, Beth Israel Hospital.
*9:00–10:00 a.m. Arthritis Grand Rounds. Robert Breck Brigham Hospital.
*10:00–11:00 a.m. Combined Medical-Surgical Rounds. Sherman Auditorium, Beth Israel Hospital.
10:30–11:15 a.m. Lecture on Diabetes for Doctors and Patients by a Member of the Joslin Clinic. Joslin Auditorium, New England Deaconess Hospital.
*11:00 a.m.–12:00 m. Thoracic Conference. Reactions to Endotracheal Anesthesia. Dr. Leroy D. Vandam. Main Amphithester, Peter Bent Brigham Hospital.
*11:00 a.m.–12:00 m. Medical Staff Conference. Sherman Auditorium, Beth Israel Hospital.
*11:00 a.m.–12:30 p.m. Hand Clinic (Physical Medicine and Rehabilitation Service). Boston City Hospital.
*12:00 m.–1:00 p.m. Surgical Staff Conference. Sherman Auditorium, Beth Israel Hospital.
*12:15–1:15 p.m. Orthopedic Clinic. Amphitheater, Peter Bent Brigham Hospital.
*3:15–5:15 p.m. Pediatric-Child Psychiatry Seminar. Burnham Memorial Hospital for Children (Burnham 4), Massachusetts General Hospital.

FRIDAY, MAY 20

*8:00–8:45 a.m. Case Presentations. Joslin Clinic. Joslin Auditorium, New England Deaconess Hospital.
*9:30–11:30 a.m. Medical and Surgical Grand Rounds. Drs. George W. Thorn and Francis D. Moore. Main Amphitheater, Peter Bent Brigham Hospital.
*10:00 a.m. Tuberculosis Surgical Clinic. South End Health Unit, 57 East Concord Street.
10:30–11:15 a.m. Lecture on Diabetes for Doctors and Patients by a Member of the Joslin Clinic. Joslin Auditorium, New England Deaconess Hospital.
*11:00 a.m.–1:00 p.m. Medical Grand Rounds. Dr. Proger and Staff. Stearns Auditorium, New England Center Hospital.
*1:30 p.m. Fertility and Endocrine Clinic. Free Hospital for Women, Brookline.
*1:30 p.m. Tumor Clinic. Mount Auburn Hospital, Cambridge.
*4:00–10:00 p.m. Alcoholism Clinic. By appointment. Washingtonian Hospital, 41 Morton Street, Jamaica Plain.
*8:00 p.m. New England Rheumatism Society. Spring Meeting. Stearns Auditorium, New England Medical Center.

SATURDAY, MAY 21

*8:00–8:45 a.m. Case Presentations. Joslin Clinic. Joslin Auditorium, New England Deaconess Hospital.
*8:00–9:00 a.m. Anesthesia Conference. Dr. Etsten. Pratt Lecture Hall, Joseph H. Pratt Diagnostic Hospital.
*8:30–10:00 a.m. Orthopedic Staff Conference. Boston City Hospital.
*9:00–10:30 a.m. Surgical Grand Rounds. Dr. Child and Staff. Stearns Auditorium, New England Center Hospital.
10:30–11:15 a.m. Lecture on Diabetes for Doctors and Patients by a Member of the Joslin Clinic. Joslin Auditorium, New England Deaconess Hospital.
*11:00 a.m.–12:00 m. Hematology Clinic. Dr. William Dameshek. Pratt Lecture Hall, Joseph H. Pratt Diagnostic Hospital.

*(Concluded on page xxxii)*